

AUTHOR QUERY FORM

**LIPPINCOTT  
WILLIAMS AND WILKINS**

**JOURNAL NAME: BCO**

**ARTICLE NO: COP\_S\_14\_00175**

**QUERIES AND / OR REMARKS**

QUERY NO.	Details Required	Author's Response
Q1	Please provide the volume number and page range for this chapter in reference [5].	
Q2	Please check as we have abrivated all authors first name in reference [30].	
Q3	Please provide the volume number for this chapter in reference [47].	

# Successful treatment of infected femoral shaft nonunion with teriparatide after irradiation of infection

Andreas Panagopoulos, MD, PhD, Dimitrios Ntourantonis, MD, MSc,  
Antonis Kouzelis, MD, PhD and Panagiotis Megas, MD, PhD

*Orthopaedic Department, Patras University Hospital, Greece*

## INTRODUCTION

One healing requires a multitude of cell types, inflammatory cytokines, growth factors, prostaglandins, and other substances to restore biomechanical properties.<sup>1</sup> The biologic process of fracture healing is complex, and several factors may impede or enhance this process.<sup>2-4</sup> Delayed or nonunion of long bone fractures continues to have a high incidence despite modern treatment options, often leaving patients with residual physical disability.<sup>5</sup> Femoral nonunion presents a difficult treatment challenge and a formidable personal and economic hardship for the patient. A number of techniques have been proposed for treating nonunion of the femoral shaft, including electromagnetic fields, low-intensity ultrasound, extracorporeal shock wave therapy and various surgical options such as nail dynamization, exchange nailing, external fixators, augmented or wave-plate osteosynthesis and other complex reconstructive techniques.<sup>6</sup> Plating is the treatment of choice for femoral nonunion if an intramedullary nail is in situ, and reamed intramedullary nailing is the treatment of choice for failed plate fixation.<sup>7</sup> Enhancement of the biologic environment at the nonunion site can be achieved with **with** bone grafting, bone graft substitutes, or new bioactive factors.<sup>8,9</sup>

Pharmacological agents that modulate bone formation and bone remodeling are in broad use for treatment of osteoporosis and bone fragility, but interest in their use in fracture repair has recently emerged.<sup>9-14</sup> Teriparatide is a synthetic polypeptide hormone that contains the 1-34 amino acid fragment of recombinant human parathyroid hormone (PTH 1-34). It has been approved for the treatment of postmenopausal women with osteoporosis who are at high risk for sustaining a fragility fracture, with demonstrated increases in bone mineral density.<sup>15,16</sup> Recent animal studies have suggested that PTH (1-34) may be effective in enhancing fracture healing, showing that callus forms earlier and has superior biomechanical properties than

those without PTH (1-34) treatment.<sup>17-19</sup> Although studies suggest a potential clinical role for PTH (1-34),<sup>20-22</sup> one study in postmenopausal women showed no benefit of teriparatide use in distal radial fracture healing.<sup>23</sup>

Anecdotal literature on the use of teriparatide in promoting bone healing suggests its efficacy, and reports of successful treatment of nonunions are rapidly increasing.<sup>24</sup> Teriparatide seems useful in the treatment of atypical femoral fractures after long-term administration of bisphosphonates.<sup>25,26</sup> The effect of teriparatide in nonunions range from an acceleration of the healing process to its reactivation in atrophic nonunions, but these cases refer to fractures in various sites, both in cancellous and cortical bone, often in patients with risk factors for nonunion, and some after initial conservative treatment of fractures.<sup>26-33</sup> A systematic literature review on the use of recombinant PTH in human fracture healing yielded only 16 publications on the subject, including 13 case reports or series and two randomized controlled trials. In eight case reports, treatment was initiated for delayed union or chronic nonunion, resulting in callus formation at 1-3 mo with a decrease in fracture gap. Complete resolution of pain and final healing of the nonunions was seen in 5-21 mo.<sup>34</sup>

We present a patient with an atrophic femoral nonunion after plate fixation, complicated by low-grade infection. The patient was treated successfully with off-label use of teriparatide for 3 mo, confirming a possible benefit in using teriparatide in long-bone nonunions. To the best of our knowledge, we believe this is the first case report in the literature of an infected nonunion of a long-bone diaphyseal fracture treated with teriparatide. According to Greek law, ethical approval for this study was not required; however, written informed consent was obtained from the patient for surgical treatment, off-label use of teriparatide, and publication of her information.

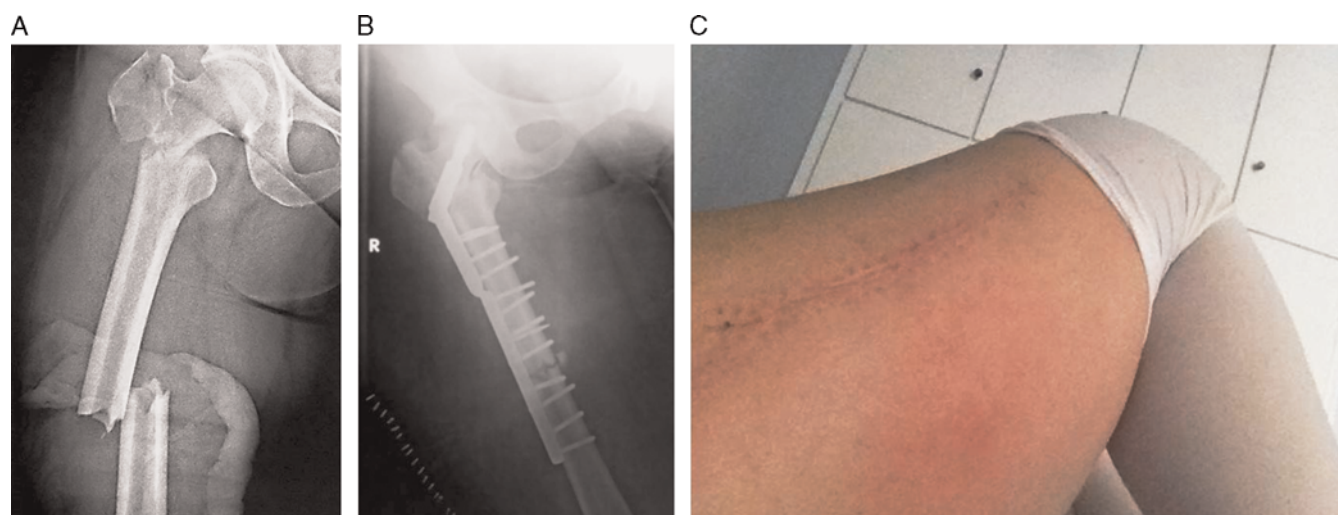
## CASE REPORT

A 54-year-old woman was involved in a high-energy traffic accident in March 2011. She was diagnosed with right ipsilateral femoral fracture in the trochanteric area and a midshaft fracture of the femur (Figure 1A). She underwent surgery at another institution, which consisted of Dynamic Hip Screw (DHS) fixation for the trochanteric fracture and a 4.5-mm compression plate for the femoral fracture next to the DHS plate (Figure 1B). In April 2013, 13 mo later, she

### Financial Disclosure: The authors report no conflicts of interest.

Correspondence to Andreas Panagopoulos, MD, PhD, Assistant Professor in Orthopaedics, Patras University Hospital, Orthopaedic Department, Papanikolaou Street 1, 26504 Rio-Patras, Greece  
Tel: +00306944363624; fax: +00302610994657;  
e-mail: andpan21@gmail.com.

1940-7041 Copyright © 2015 Wolters Kluwer Health, Inc. All rights reserved.

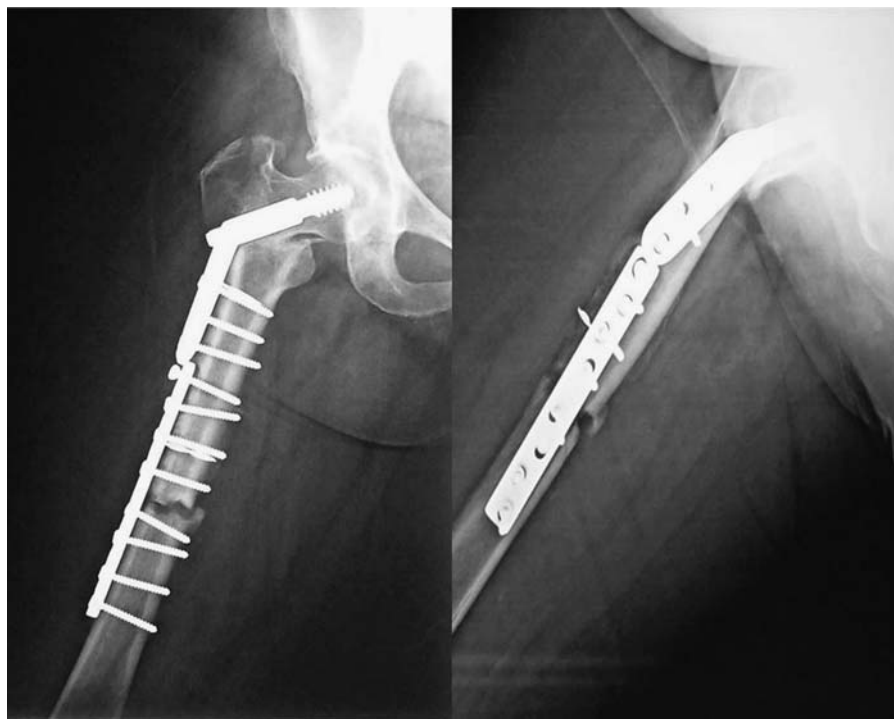

**FIGURE 1.** (A) Anteroposterior view of the right femur showing an ipsilateral fracture involving the trochanteric area and the midshaft of the diaphysis. (B) Postoperative radiograph showing the mode of fixation chosen in another hospital: DHS for the trochanteric fracture and compression plate for the diaphyseal fracture. (C) Clinical picture of the lateral thigh showing redness below the surgical incision 13 mo postoperatively.

presented to our outpatient department complaining of pain on weightbearing and the inability to walk without support despite the rehabilitation program that she had followed for at least 7 mo. On physical examination she had a full, painless range of motion of the hip joint and slight tenderness on palpation at the anterior thigh. There was knee pain during flexion and extension and decreased range of motion. Edema and redness were observed on the lateral side of the right femur, just below the surgical incision (Figure 1C). No signs of purulent discharge were observed or mentioned by the patient. The skin was quite warm compared with the opposite side. She had had no fever or other signs of systemic disease during the last 13 mo. Laboratory tests, including white blood cell counts, hemoglobin, renal and liver function, serum alkaline phosphatase, PTH, calcium, and Vitamin D were all within normal range. Erythrocyte sedimentation rate (ESR) was slightly elevated (25 mm/Hr. normal range 1–30) and C-reactive protein (CRP) was elevated (1.8, normal level < 0.8) indicating a low-grade superficial infection. The patient denied smoking, alcohol abuse, and had no history of metabolic disease or glucocorticoid intake. Anteroposterior and lateral radiographs of the femur revealed a healed trochanteric fracture in a malunited position and an established atrophic nonunion of the femoral diaphyseal fracture (Figure 2). Loosening of the two proximal screws of the plate and two broken drills inside the bone also were noted. The patient was admitted to our hospital for further investigation and treatment. As the diagnosis of nonunion complicated by low-grade infection was established, the patient was offered one of two treatments that would be based on the intraoperative findings. In case of explicit infectious signs, such as drainage of pus from the surgical site, we would proceed to implant removal, irrigation of the wound, removal of debris, and fixation with monolateral or circular external fixation. In the absence of pus or other warning signs, we would proceed to thorough surgical debridement and irrigation, exchange of the implants for a long

trochanteric nail or a long DCS (Dynamic Condylar Screw) plate in order to correct the hip deformity at the same time. The patient did not consent to these types of interventions and asked for something less invasive, including biological intervention. Despite our warnings that a less invasive surgery would be inadequate, the patient was taken to the operating theater for culture, wound irrigation, and debridement of the nonunion site. The patient was open to the possibility of exchanging the plate in case of loosening. Intraoperatively, no pus was noted in the surgical wound except for some yellowish fluid. The muscles and surrounding tissues looked quite healthy. The nonunion was explored and debrided. All the pseudarthrotic material was removed and six cultures obtained from different sites including the medullary canal. Interestingly, the plate was stable and no movement of the fractured parts was seen during knee motion. The two proximal screws were loose and were replaced using diverging drill directions. The medullary canal was freshened with multiple drills at both ends of the cortical bone, and cancellous bone grafting from the iliac crest was impacted into the nonunion site for biological enhancement of healing. Twenty-four hours after the procedure one of the six cultures was positive for *Staphylococcus epidermidis*. The particular bacterium is sensitive to almost all the proposed antibiotics in the antibiogram. According to our hospital's infectious disease protocol, our patient was administered ciprofloxacin, 500 mg twice a day and rifabacin 600 mg daily for 8 wk. The patient was discharged from the hospital on the 7th postoperative day in a good clinical condition and without any further complications. Detailed instructions concerning medication, partial weightbearing, and physiotherapy were given to the patient as well as scheduled monthly appointments for clinical, radiographic, and laboratory testing.

During the postoperative period she was consistent in taking her medication and keeping outpatient appointments. The ESR and CRP levels were back to normal after the first month, and there was no evidence of infection from the



**FIGURE 2.** Anteroposterior and lateral radiographs of the right femur 13 mo postoperatively. Atrophic nonunion of the diaphyseal fracture, malunion in the trochanteric area, loosening of two proximal screws and two broken drills inside the medullary canal.

surgical trauma. The pattern of pain did not change, however, and she was still unable to walk without the use of crutches. Radiographs taken at 1, 3, and 5 mo postoperatively confirmed the presence of a persistent atrophic nonunion of the diaphyseal femoral fracture: the fracture gap persisted, fracture margins were sclerotic, and there was no evidence of callus at the fracture site (Figure 3A and B). The patient was reluctant to have another surgery, and she consented to off-label teriparatide therapy at doses approved for the treatment of osteoporosis (20 mg/day). Twenty days after the initiation of teriparatide the patient mentioned for first time that the pain was getting better and that she was able to bear weight with only one crutch. Radiographs at 2 mo showed findings of union, with bone bridges between the fracture fragments and decrease of the fracture gap. At 3 mo after teriparatide treatment she was able to ambulate full weight bearing without crutches. The ESR and CRP levels were normal, and the patient did not mention any sign of systemic inflammatory response during the last 3 mo. She had no pain during daily activities, and she returned to office work 1 mo later. Radiographs at 3 mo showed complete healing of the nonunion (Figure 3C and D). There were no teriparatide-related side effects during or after the treatment. Final radiographs at 12 mo after teriparatide treatment showed solid union at the fracture site and increased density of the callus (Figure 3E and F).

## DISCUSSION

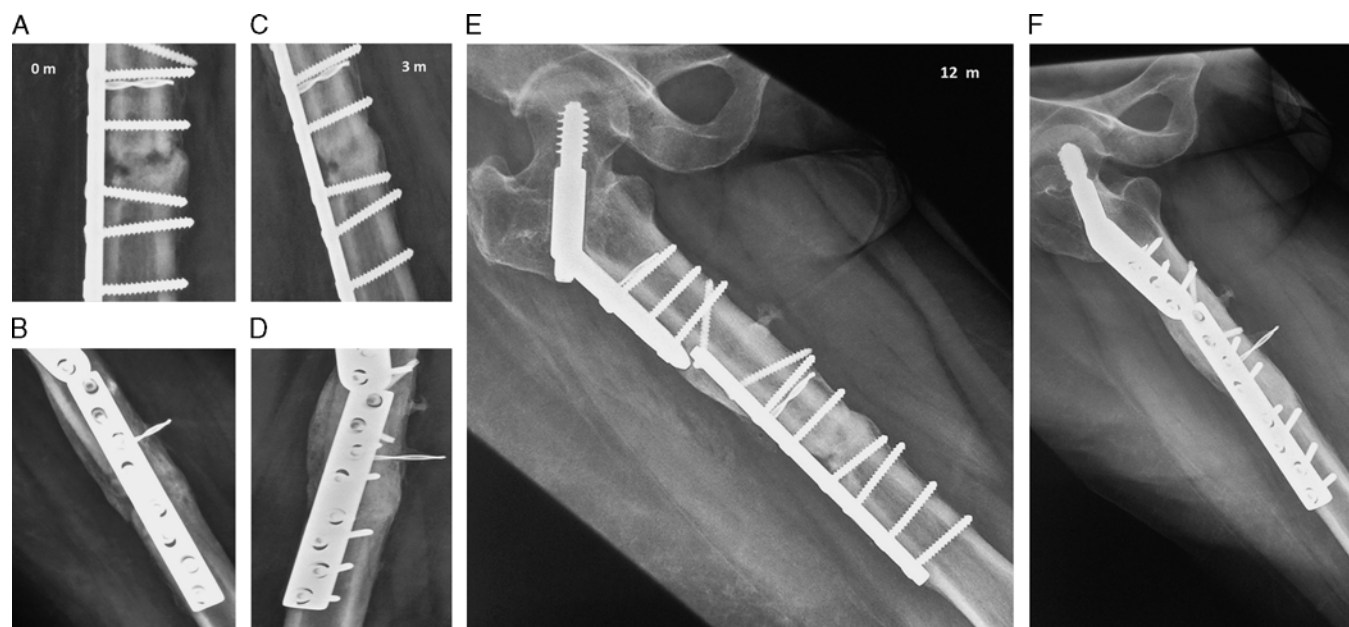
The most important finding of the current report is that teriparatide is likely to be a potent agent for enhancing fracture healing in patients with established nonunion of a

long bone in a poor biological environment. We are considering the crucial role of teriparatide in our patient because the fracture site of the femoral shaft showed no signs of bone healing 13 mo after the initial fixation and 5 mo after the second intervention. It is important to mention that our patient did not receive any other pharmacological agent except antibiotics during the whole postoperative period (since April 2013) that could have affected the progression of callus formation. The duration of the antibiotic treatment was 8 wk, and there was no overlapping period with teriparatide administration that started 5 mo after the second operation. Although there were no clinical and laboratory signs of persistent infection just before the initiation of teriparatide, we cannot be sure that the infection was a contributing factor in the persistence of nonunion.

Although many treatment methods have been developed, controversy exists regarding the optimal management of ipsilateral femoral neck and shaft fractures. DHS combined with compression plating or long intramedullary nailing are both acceptable methods of fixation.<sup>35,36</sup> Wang *et al.*,<sup>37</sup> in a retrospective comparative study of both techniques, found similar results in regards to union time, complication rate, and overall functional outcome; however, the nail was a better option for the treatment of complex fractures and had the advantages of minimal exposure, reduced perioperative blood loss, and biological fixation of both fractures with a single implant. In our level 1 trauma center we also favor intramedullary nailing for these types of fractures.<sup>38</sup>

The nonunion in our patient was further complicated by the presence of a low-grade infection, luckily by a bacterium of low potency and sensitive to most antibiotics. Infected





**FIGURE 3.** (A and B) Anteroposterior and lateral radiographs of the femur 5 mo after the reoperation (18 mo from the initial trauma) that confirms the presence of a persistent atrophic nonunion of the diaphyseal femoral fracture. The fracture gap is open, fracture margins are sclerotic, and there is no evidence of callus at the fracture site, (C and D) Anteroposterior and lateral radiographs of the femur 3 mo after the administration of teriparatide. The fracture gap has been eliminated and callus formation is seen on both the anteroposterior and lateral views. (E and F) Anteroposterior and lateral radiographs of the femur 12 mo after the administration of teriparatide. The fracture gap has almost disappeared and callus formation is solid and dense.

nonunion is a major and complex orthopaedic problem. Various treatment modalities have been adopted to manage this condition, but in almost all cases the first priority is the eradication of the infection. Staged bone grafting, external fixation, repeat internal fixation, antibiotic impregnated cement nailing, or more complex procedures are required later.<sup>39–41</sup> Jain and Sinha<sup>42</sup> stated that in infected nonunions the crucial factors relating to treatment and prognosis are the bone gap and the presence of symptomatic active infection. They classified infected nonunions into two categories: type A is infected nonunion of a long bone with nondraining (quiescent) infection, with or without implant in situ, and type B is an infected nonunion of a long bone with draining (active) infection. Both are classified further into two subtypes: (1) nonunion with a bone gap smaller than 4 cm, or (2) nonunion with a bone gap larger than 4 cm. Our patient had an A1 nonunion, and single-stage debridement and bone grafting with fracture stabilization were done as indicated. Adequate debridement, fracture stabilization, and second-stage bone grafting also gives desirable results in type B1 infected nonunions. Distraction osteogenesis is the preferred procedure for types A2 and B2 infected nonunions. Another option for our patient would have been to replace the distal screws as we did for the loose proximal ones so that a compression device could have been applied to the lower end of the plate to eliminate the fracture gap. Because the nonunion gap was very small and the cancellous graft was well impacted, we did not proceed to this exchange.

Although there have been several studies and case reports on teriparatide use in patients with fracture nonunion of the humerus, femoral neck, thoracic and lumbar spine, radius,

odontoid, sternum, pubic ramus, ankle, and metatarsals, as well as atypical femoral fractures,<sup>25–34,43</sup> there are only three reports of successfully healed nonunions of the femur and one recent case series of femoral and tibial fractures.<sup>44–47</sup> Paridis and Karachalios<sup>44</sup> reported comminuted, two-level (peritrochanteric and middiaphyseal) femoral fractures in a 48-year-old man (heavy smoker) after a road traffic accident. The types of fractures were similar to those in our patient. Their patient initially underwent internal fixation of both fractures with a hip sliding screw and a dynamic compression plate. He had structural failures, first of the initial plate and later of a long locking plate, and ended up with an extended area of nonunion. The third operation was in the form of a Taylor Spatial Frame<sup>TM</sup> (Smith and Nephew, Memphis, TN) with autografting and use of bone morphogenetic protein (BMP)-7. The nonunion persisted but finally united after 2 mo of PTH (1–34). Lee *et al.*<sup>45</sup> reported three patients with persistent femoral nonunions, one in the distal femur treated initially with locking plate, one in the proximal part treated initially with multiple cannulated screws, and one in the diaphysis treated initially with retrograde intramedullary nailing. Teriparatide was administered for 3–9 mo after a diagnosis of nonunion. A successful union was obtained in all three patients without further surgical intervention and no adverse events. Giannotti *et al.*<sup>46</sup> reported an 80 year-old woman who sustained a right distal metaphyseal femoral fracture at total knee arthroplasty. She underwent open reduction internal fixation with a lateral femoral locking plate. Radiographs at 5 and 7 mo did not show any signs of healing. After 2 mo of treatment with teriparatide, the radiograph showed the presence of bony bridges and a decreased gap between

1 fragments and a different aspect of neoformed bone. After  
3 mo of treatment, healing was complete. Finally, Mancilla  
3 *et al.*<sup>47</sup> reported recently six patients between the ages of  
19–64 yr with tibial or femoral fractures that had not healed  
5 for 3–36 mo and were treated with teriparatide (20 µg/day).  
Accelerated healing of fracture nonunion was confirmed in  
7 five of six patients with time to complete union of 3–9 mo.  
Interestingly, the shortest time to recovery was observed in  
9 younger patients without comorbidities.

11 Femoral nonunion is a challenge for the patient as well as  
the surgeon. To date, it has been treated by various surgical  
13 interventions, with only minimal focus on medical ap-  
proaches. We report that teriparatide is a possible adjunct to  
15 treatment in difficult cases of nonunion. To the best of our  
knowledge our report of successful teriparatide treatment in  
17 femoral nonunion complicated by low-grade infection is the  
first in the literature. Of further importance is the rapid  
19 response to the medication and the subsequent clinical and  
radiographic improvement in such a short period of time  
21 (3 mo). The potential benefit of teriparatide as an adjunct in  
the treatment of nonunion justifies prospective, random-  
23 ized, placebo-controlled trials to determine its efficacy and  
safety in different populations with varying comorbidities  
25 and types of nonunions.

## 27 REFERENCES

1. Borrelli J Jr, Pape C, Hak D, *et al.* Physiological challenges of bone repair. *J Orthop Trauma.* 2012; 26:708–711.
2. Sathyendra V, Darowish M. Basic science of bone healing. *Hand Clin.* 2013; 29:473–481.
3. Egol KA, Bechtel C, Spitzer AB, *et al.* Treatment of long bone nonunions: factors affecting healing. *Bull NYU Hosp Jt Dis.* 2012; 70:224–231.
4. Niikura T, Lee SY, Sakai Y, *et al.* Causative factors of fracture nonunion: the proportions of mechanical, biological, patient-dependent, and patient-independent factors. *J Orthop Sci.* 2014; 19:120–124.
5. Tay WH, de Steiger R, Richardson M, *et al.* Health outcomes of delayed union and nonunion of femoral and tibial shaft fractures. *Injury.* 2014; ■:■. [Epub ahead of print].
6. Lambiris E, Panagopoulos A, Zouboulis P, *et al.* Current concepts: aseptic nonunion of femoral shaft diaphysis. *Eur J Trauma Emerg Surg.* 2007; 33:120–134.
7. Somford MP, van den Bekerom MP, Kloen P. Operative treatment for femoral shaft nonunions, a systematic review of the literature. *Strategies Trauma Limb Reconstr.* 2013; 8:77–88.
8. Roberts TT, Rosenbaum AJ. Bone grafts, bone substitutes and orthobiologics: the bridge between basic science and clinical advancements in fracture healing. *Organogenesis.* 2012; 8:114–124.
9. Giannotti S, Bottai V, Dell'osso G, *et al.* Current medical treatment strategies concerning fracture healing. *Clin Cases Miner Bone Metab.* 2013; 10:116–120.
10. Bukata SV. Systemic administration of pharmacological agents and bone repair: what can we expect. *Injury.* 2011; 4:605–608.
11. Pietrogrande L, Raimondo E, Fossali A, *et al.* Biological and pharmacological factors influencing the fracture healing. *Aging Clin Exp Res.* 2011; 23(2 Suppl):65–68.
12. Goldhahn J, Little D, Mitchell P, *et al.* Evidence for anti-osteoporosis therapy in acute fracture situations—recommendations of a multi-disciplinary workshop of the International Society for Fracture Repair. *Bone.* 2010; 46:267–271.
13. Goldhahn J, Féron JM, Kanis J, *et al.* Implications for fracture healing of current and new osteoporosis treatments: an ESCEO consensus paper. *Calcif Tissue Int.* 2012; 90:343–353.
14. Jørgensen NR1, Schwarz P. Effects of anti-osteoporosis medications on fracture healing. *Curr Osteoporos Rep.* 2011; 9:149–155.
15. Cipriano CA, Issack PS, Shindle L, *et al.* Recent advances toward the clinical application of PTH (1-34) in fracture healing. *HSS J.* 2009; 5:149–153.
16. Neer RM, Arnaud CD, Zanchetta JR. Effect of parathyroid hormone (1-34) on fractures and bone mineral density in postmenopausal women with osteoporosis. *N Engl J Med.* 2001; 344:1434–1441.
17. Alkhiary YM, Gerstenfeld LC, Krall E. Enhancement of experimental fracture-healing by systemic administration of recombinant human parathyroid hormone (PTH 1-34). *J Bone Joint Surg Am.* 2005; 87:731–741.
18. Komatsubara S, Mori S, Mashiba T. Human parathyroid hormone (1-34) accelerates the fracture healing process of woven to lamellar bone replacement and new cortical shell formation in rat femora. *Bone.* 2005; 36:678–687.
19. Manabe T, Mori S, Mashiba T, *et al.* Human parathyroid hormone (1-34) accelerates natural fracture healing process in the femoral osteotomy model of cynomolgus monkeys. *Bone.* 2007; 40:1475–1482.
20. Cheng ML, Gupta V. Teriparatide - Indications beyond osteoporosis. *Indian J Endocrinol Metab.* 2012; 16:343–348.
21. Zeng X, He H, Zhang L, *et al.* A potential therapeutic approach to overload-induced bone loss around implant: parathyroid hormone (PTH). *Med Hypotheses.* 2011; 77:701–704.
22. Bashutski JD, Eber RM, Kinney JS, *et al.* Teriparatide and osseous regeneration in the oral cavity. *N Engl J Med.* 2010; 363:2396–2405.
23. Aspenberg P, Genant HK, Johansson T, *et al.* Teriparatide for acceleration of fracture repair in humans: a prospective, randomized, double-blind study of 102 postmenopausal women with distal radial fractures. *J Bone Miner Res.* 2010; 25:404–414.
24. Pietrogrande L, Raimondo E. Teriparatide in the treatment of non-unions: scientific and clinical evidences. *Injury.* 2013; 44(Suppl 1):S54–S57.
25. Reddy SV, Gupta SK. Atypical femoral shaft fracture in a patient with nonmetastatic prostate cancer on zoledronic acid therapy: effect of therapy or coincidence? *Singapore Med J.* 2012; 53:52–54.
26. Chiang CY1, Zebaze RM, Ghasem-Zadeh A, *et al.* Teriparatide improves bone quality and healing of atypical femoral fractures associated with bisphosphonate therapy. *Bone.* 2013; 52:360–365.
27. Corradini C, Macchia M, Malagoli E. Enhanced healing of lateral femoral neck fractures in elderly women with teriparatide: new therapeutic horizon. *Osteoporos Int.* 2010; 21:S177–S178.
28. Di Bisceglie L, Fata G, Di Molfetta V. Teriparatide use to accelerate fracture repair in delayed healing of complex fractures in military personnel: a case report. *Calcif Tissue Int.* 2007; 80:S50–S51.
29. Rubery PT, Bukata SV. Teriparatide may accelerate healing in delayed unions of type III odontoid fractures A report of 3 Cases. *J Spinal Disord Techn.* 2010; 23:151–155.
30. Wu CC, Wei JC, Hsieh CP. Enhanced healing of sacral and pubic insufficiency fractures by teriparatide. *J Rheumatol.* 2012; 39:1306–1307.
31. Oteo-Alvaro A, Moreno E. Atrophic humeral shaft nonunion treated with teriparatide (rh PTH 1–34): a case report. *J Shoulder Elbow Surg.* 2010; 19:e22–e28.
32. Chintamaneni S, Finzel K, Gruber BL. Successful treatment of sternal fracture non-union. *Osteoporos Int.* 2010; 21:1059–1063.
33. Tamai K1, Takamatsu K, Kazuki K. Successful treatment of nonunion with teriparatide after failed ankle arthrodesis for Charcot arthropathy. *Osteoporos Int.* 2013; 24:2729–2732.
34. Zhang D, Potty A, Vyas P, *et al.* The role of recombinant PTH in human fracture healing: a systematic review. *J Orthop Trauma.* 2014; 28:57–62.
35. Watson JT, Moed BR. Ipsilateral femoral neck and shaft fractures: complications and their treatment. *Clin Orthop Relat Res.* 2002; 399:78–86.
36. Jain P, Maini L, Mishra P, *et al.* Cephalomedullary interlocked nail for ipsilateral hip and femoral shaft fractures. *Injury.* 2004; 35:1031–1038.

- 1 37. Wang WY, Liu L, Wang GL, *et al.* Ipsilateral basicervical femoral neck and shaft fractures treated with long proximal femoral nail  
3 antirotation or various plate combinations: comparative study. *J Orthop Sci.* 2010; 15:323–330.
- 5 38. Lambiris E, Giannikas D, Galanopoulos G, *et al.* A new  
7 classification and treatment protocol for combined fractures of  
9 the femoral shaft with the proximal or distal femur with closed  
11 locked intramedullary nailing: clinical experience of 63 frac-  
13 tures. *Orthopedics.* 2003; 26:305–308.
- 15 39. Prasarn ML, Ahn J, Achor T, *et al.* Management of infected  
femoral nonunions with a single-staged protocol utilizing  
internal fixation. *Injury.* 2009; 40:1220–1225.
40. Ueng SW, Wei FC, Shih CH. Management of femoral diaphyseal  
infected nonunion with antibiotic beads local therapy, external  
skeletal fixation, and staged bone grafting. *J Trauma.* 1999;  
46:97–103.
41. Shyam AK, Sancheti PK, Patel SK, *et al.* Use of antibiotic cement-  
impregnated intramedullary nail in treatment of infected non-  
union of long bones. *Indian J Orthop.* 2009; 43:396–402.
42. Jain AK, Sinha S. Infected nonunion of the long bones. *Clin  
Orthop Relat Res.* 2005; 431:57–65. 17
43. Carvalho NN, Voss LA, Almeida MO, *et al.* Atypical femoral fractures  
during prolonged use of bisphosphonates: short-term responses to  
strontium ranelate and teriparatide. *J Clin Endocrinol Metab.* 2011;  
96:2675–2680. 19
44. Paridis D, Karachalios T. Atrophic femoral bone nonunion  
treated with 1-84 PTH. *J Musculoskelet Neuronal Interact.* 2011;  
11:320–322, quiz 323. 21
45. Lee YK, Ha YC, Koo KH. Teriparatide, a nonsurgical solution for  
femoral nonunion? A report of three cases. *Osteoporos Int.* 2012;  
23:2897–2900. 23
46. Giannotti S, Bottai V, Dell'Osso G, *et al.* Atrophic femoral  
nonunion successfully treated with teriparatide. *Eur J Orthop  
Surg Traumatol.* 2013; 23(Suppl 2):S291–S294. 25
47. Mancilla EE, Brodsky JL, Mehta S, *et al.* Teriparatide as a systemic  
treatment for lower extremity non-union fractures: A case  
series. *Endocr Pract.* 2014; ■:1–22. [Epub ahead of print]. 27
- AQ3