

Least possible fixation techniques of 4-part valgus impacted fractures of the proximal humerus: a systematic review

Andreas Panagopoulos, Irini Tatani, Dimitrios Ntourantonis, Ioannis Seferlis, Antonis Kouzelis, Minos Tyllianakis
 Department of Shoulder and Elbow Surgery, University Hospital of Patras, Greece

Abstract

The valgus-impacted (VI) 4-part fractures are a subset of fractures of the proximal humerus with a unique anatomic configuration characterized by a relatively lower incidence of avascular necrosis after operative intervention. We systematically reviewed clinical studies assessing the benefits and harms of least possible fixation techniques (LPFT) for this unique fracture type. Such information would be potentially helpful in developing an evidence-based approach in the management of these complex injuries. We performed analytic searches of PubMed, Embase, Web of Science, Google Scholar and the Cochrane Library, restricting it to the years 1991-2014. Included studies had to describe outcomes and complications after primary osteosynthesis with any type of LPFT apart from plate-screws and intramedullary nailing. Eligibility criteria were also included English language, more than 5 cases, minimum follow up of one year and report of clinical outcome using at least one relevant score (Constant, Neer or ASES). Based on 292 database hits we identified 12 eligible studies including 190 four-part valgus impacted fractures in 188 patients. All eligible studies were case series composed of min 8 to max 45 patients per study. The gender distribution was 60% (112) female and 40% (76) male. The average age of the patients at the time of injury was 54.5 years. In 8/12 studies an open reduction was used for fracture fixation using different surgical techniques including KW, cerclage wires, cannulated screws and osteosutures. Closed reduction and percutaneous fixation was used in 4 studies. Mean follow-up time ranged from 24 to 69 months. A good functional outcome (constant score >80) was reported in 9/12 studies. The most common complication was avascular necrosis of the humeral head with an overall incidence of 11% (range, 0-26.3%). Total avascular necrosis (AVN) was found in 15/188 patients (7.9%) and was more common in per-

cutaneous techniques and partial AVN in 6/188 (3.1%) being more common in open techniques. The overall re-operation rate was very low (3.7%). Insufficient study designs cannot provide definite treatment recommendations and quantitative data synthesis of outcome. In general, LPFT for 4-part VI fractures leads to satisfactory outcomes with low incidence of complications. A considerable risk of biases can be attributed to fracture classification, proper radiological control, mean age of patients, mixed types of fixation methods, non-age adjusted clinical scoring and small follow up periods. These factors are discussed in detail. Level of evidence: systematic review of literature (level IV) as most of the studies were level IV.

Introduction

The valgus-impacted (VI) four-part fractures are a subset of fractures of the proximal humerus with a unique anatomic configuration. Accounting for approximately 14% of all humeral head fractures, were first featured by Jacob *et al.*¹ in 1991 and were considered as a subtype of proximal humeral fractures, in which the articular segment is impacted into the metaphysis, causing spread of the greater and lesser tuberosities thus creating a fracture line through the anatomical neck, with minimal or zero disruption of the posteromedial hinge (Figure 1). Previous to Jacob's report, a similar type of fracture had been described by de Anquin and de Anquin in 1982,² as *impacted with inferior subluxation*; in 1984, Stableforth made a brief mention of an *impacted and little displaced* fracture in his review of four-part proximal humeral fractures.³

This injury pattern was not clearly described amongst the other 3- and 4-part fractures in the original Neers' classification of proximal humeral fractures for which he suggested immediate prosthetic head replacement, due to the high nonunion and osteonecrosis rates of these injuries.⁴ The AO/OTA classification contains the 4-part VI fracture in the subgroup 11-C1.1 (slight displacement) and 11-C2.1 (marked displacement).^{5,6} In 2002, CS Neer,⁷ in his updated classification had included the 4-part VI fracture, as a borderline lesion (type A) in the continuum of the lateral displacement of the head that progresses from those fractures with minimal displacement to the valgus impacted types and then on to the true displaced 4-part fracture (lateral fracture-dislocation, type B).

A 4-part VI humeral head fracture is an uncommon but important injury to be identified in patients with shoulder trauma. Failure to diagnose such an injury can lead to ongoing pain and poor function after an initial conser-

Correspondence: Andreas Panagopoulos, Department of Shoulder and Elbow Surgery, Patras University Hospital, Papanikolaou street 1, 26504 Patras-Rio, Greece.
 Tel.: + 30.694.4363624.
 E-mail: andpan21@gmail.com

Key words: 4-part valgus impacted fractures; internal fixation; least possible osteosynthesis; proximal humerus; percutaneous fixation.

Contributions: AP substantial contributions to conception and design, drafting the manuscript and critically reviewed it at the end; IT and DN collection, acquisition, analysis and interpretation of data; GS designing of tables, analysis of data and literature search; AK flow chart design, selection of included manuscripts and analysis of data; MT study concept, participated in design and coordination, helped to draft the manuscript.

Conflict of interest: the authors declare no potential conflict of interest.

Received for publication: 21 September 2015.
 Revision received: 30 October 2015.
 Accepted for publication: 2 November 2015.

This work is licensed under a Creative Commons Attribution NonCommercial 4.0 License (CC BY-NC 4.0).

©Copyright A. Panagopoulos *et al.*, 2016
 Licensee PAGEPress, Italy
 Orthopedic Reviews 2016;8:6211
 doi:10.4081/or.2016.6211

vative treatment.⁸ Treatment options range from non-operative care to internal fixation and primary shoulder hemi- or reverse arthroplasty. Non-operative treatment should be considered in elderly patients with severe morbidity and high perioperative risks. Court Brown *et al.*⁹ reported 80% good or excellent results in the largest so far study of 125 patients with predominantly stable B1.1 fractures treated non-operatively and followed for 1 year post injury. However, depending on age and fracture type, the functional outcome was less predictable with the more severe types of fractures (displaced 3- and 4- part, valgus or not). For young active patients operative treatment is highly recommended,^{10,11} because the pull of rotator cuff tendons can lead to significant tuberosity displacement and signs of subacromial impingement, mechanical blocking of forward flexion and external rotation and early osteoarthritis (Figure 2).

Proximal humeral locking plates have been introduced relatively recently, representing a significant advancement in the treatment of these injuries as they can provide more secure fixation in osteoporotic fractures. However, several systematic reviews have shown very high rate of complications such as varus malu-

nion, screw perforation, AVN and subacromial impingement, especially in the more complex types of fractures.^{12,13} Brorson *et al.*¹⁴ reported in 2012 a systematic review of AO type C fractures (including VI types) treated with locking plate osteosynthesis and found a mean age- and sex-adjusted Constant Score ranged from 60 to 88 and an overall reoperation rate ranged from 6 to 44%. The authors recommended to avoid the routinely use of locking plates in AO/OTA Type C fractures.

Several other authors,¹⁵⁻¹⁸ in contrast, have recommended closed or open reduction and fixation of 4-part VI fractures using least possible fixation techniques (LPFT) such as isolated sutures, intramedullary pins, tension band wiring, screws and Kirschner wires. In general, these techniques provide adequate stabilization with minimal use of hardware and retention of the posteromedial hinge, especially when deltoid splitting approaches are used.^{19,20}

To our knowledge, a systematic review of LPFT in the management of 4-part VI fractures of the proximal humerus has not been per-

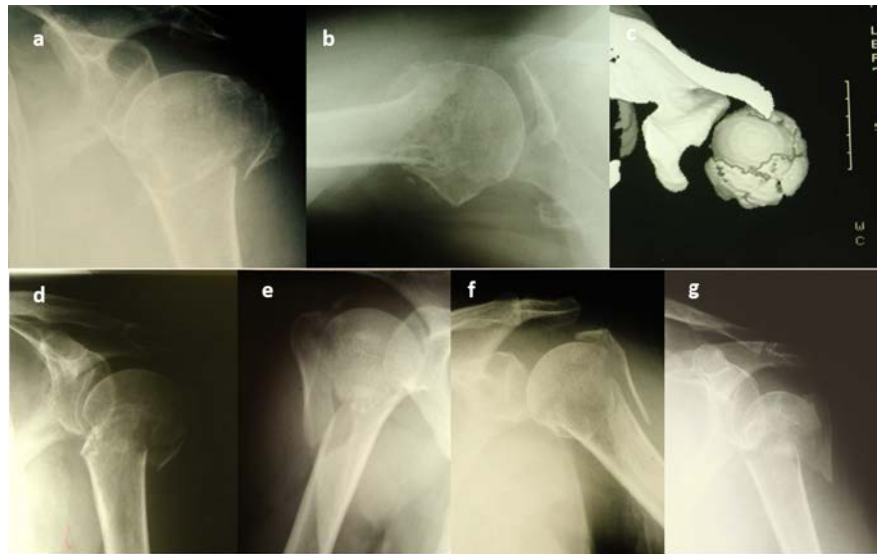

Figure 1. a-c) Typical example of 4-part VI fracture in two radiographic planes (a) anteroposterior and (b) axillary; c) computed tomography scan showing the spread of both tuberosities and the impaction of the humeral head. d-g) Other examples of 4-part valgus impacted fractures with different degrees of humeral head impaction and tuberosities displacement.

Table 1. Clinical studies with least possible fixation techniques for 4-part valgus impacted fractures.

Author	Year	Patients (bilateral)	Mean age, years	Mean follow-up, range (months)	Lost from final follow-up	Type of reduction, surgical technique, approach
Jakob <i>et al.</i> ¹	1991	18 (19)	49.5	50 (24-81)	0	Head elevation, closed reduction and percutaneous fixation with KW (5 pt), ORIF with wires, cerclage wires, screws (14 pt), either DSA or DPA
Resch <i>et al.</i> ²⁵	1995	22	52	36 (18-68)	0	ORIF, head elevation, relocation of tuberosities chips of cancellous bone, KW and osteosutures, DSA
*Resch <i>et al.</i> ²⁶	1997	13	54	24 (18-47)	0	Percutaneous fixation with KW and cannulated screws
Yu <i>et al.</i> ²²	2002	8 (9)	56	26 (10-63)	0	ORIF with a screw-wiring technique, autologous bone grafting, DPA
Hockings <i>et al.</i> ²³	2002	11	55	69 (24-131)	2	ORIF with transosseous sutures after humeral head elevation, DPA
*Gerber <i>et al.</i> ²¹	2004	8	48.8	63 (25-131)	0	ORIF, head elevation, transosseous sutures & grafting (5pt), pinning (2pt), sutures, grafting and plate (1pt), DPA
Panagopoulos <i>et al.</i> ²⁰	2004	15	45	40 (36-46)	1	ORIF with transosseous suturing, no head elevation, DSA
*Dimakopoulos <i>et al.</i> ¹⁵	2007	45	49	52 (24-108)	4	ORIF with transosseous suturing, no head elevation, DSA
Atalaret <i>et al.</i> ²⁸	2007	10	54	38.8 (35-67)	0	QRIF with transosseous sutures, head elevation, bone grafting, DPA
*Keener <i>et al.</i> ¹⁷	2007	12	56.8	35 (12-77)	n/a	Percutaneous fixation with KW and/or screws
*Bogner <i>et al.</i> ²⁴	2008	16	79 [#]	33.8 (5.8-81) [#]	n/a	Percutaneous pinning (Humerus block) and cannulated screws
Ogawa <i>et al.</i> ²⁷	2011	10	55.5	33.8 (12-77)	3	Retrograde intramedullary multiple pinning trough deltoid "V" 3 pt additional ORIF for tuberosity fixation (DSA)
Total	188 (190)	54.5	40.95	10/160 (6.25%)		

*Manuscripts with mixed types of proximal humeral fractures in mixed population of 3- and 4-part fractures; [#]mean age and follow up. ORIF, open reduction and internal fixation; n/a; not available; DSA, deltoid splitting approach; DPA, deltopectoral approach.

formed yet. Our objective in the present study is to critically evaluate the relevant literature to better quantify the expected outcomes. More specifically, we were interested in identifying data that included clinical outcomes and treatment complications, in studies that reported minimal invasive fixation techniques. Such information would be potentially helpful in developing an evidence-based approach in the management of these complex injuries.

tions of the above with the terms minimal invasive osteosynthesis, least possible fixation, percutaneous osteosynthesis, percutaneous fixation, osteosuturing, transosseous sutures and cannulated screw fixation. To eliminate the upcoming reports we also used the terms NOT plate, NOT nailing and NOT hemiarthroplasty (Figure 3).

One of the authors read reference lists from all the studies that might be eligible and two

other reviewers read the full-text version of potentially eligible reports and decided independently on study inclusion. Disagreements were discussed among all authors and resolved in consensus. Reports presenting cases of 4-part VI fractures mixed with other types of proximal humeral fractures (2-, 3- and non-VI) were excluded unless the specific cases were clearly specified in the datasheet and had adequate demographic data, clinical outcome and

Materials and Methods

Eligibility criteria

We included clinical trials, observational studies, and case series involving patients with 4-part VI fractures, according to Neer and Jacob's classifications.^{1,7} These studies should have appeared online from 1991, after Jacob's first definition, up to December 2014 and had to describe clinical outcomes and complications after primary osteosynthesis with any type of LPFT except for plate fixation (locking or not), intramedullary nailing and arthroplasty. A cut off point for LPFT was difficult to define as neither one type of hardware nor one surgical approach were used in the included reports. We defined as LPFT all types of minimal invasive hardware such as sutures, cerclage wires, screws (cannulated or not), intramedullary pins and Kirschner wires but we excluded all types of plates (tubular, T-, or buttress). For example, the study of Robinson *et al.*¹⁸ who reported on 25 patients with severely impacted 4-part VI fractures treated with *positional* screws and Norian SRS substitute was excluded from the final review because a small buttress plate was additionally used in 11/25 patients.

Eligibility criteria were also included English language, more than 5 cases, minimum follow up of one year and report of final outcome using at least one relevant score (Constant, Neer or ASES). We excluded studies of other fracture patterns (2-, 3- and displaced 4-part fractures, fracture-dislocations and splitting head fractures), as well as studies conducted on children (mean age <18), cadavers, pathological fractures, or non-clinical anatomical and biomechanical studies.

Search strategy

We performed analytical search of PubMed, Embase, Web of Science, Google Scholar and the Cochrane Library, restricting it to the years 1991-2014 (December). The query was 4-part fractures of proximal humerus or 4-part fractures or valgus impacted fractures or 4-part valgus impacted fractures or fractures with valgus impaction or C1.1, C2.1 proximal humeral fractures. In addition we searched combina-

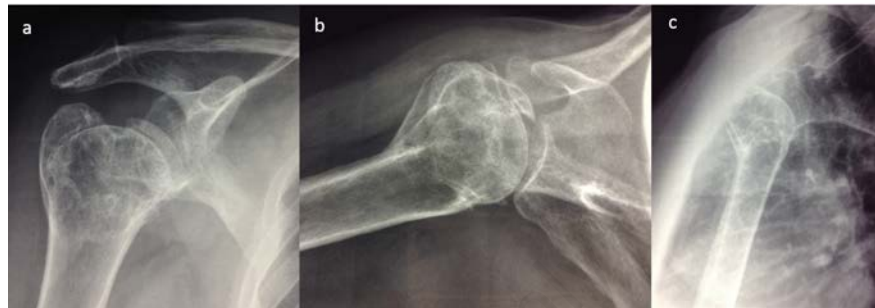

Figure 2. Malunion and tuberosities displacement in a 44 years-old female patient after conservative management of a 4-part valgus impacted fracture treated conservatively in another hospital. The patient has 145 degrees of forward elevation, limited external rotation and Constant score 65.

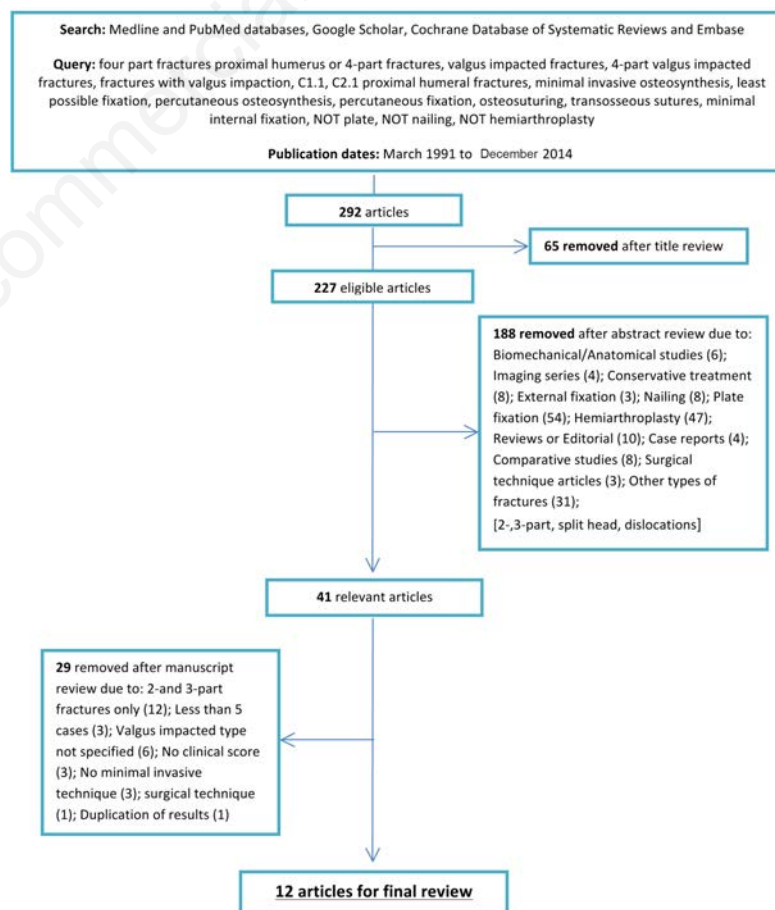


Figure 3. Flowchart of medical databases search methodology.

Table 2. Clinical outcome and complications in 188 patients.

Authors	Patients/ bilateral	Clinical score	Patient satisfaction	Overall complications	AVN % Total/partial	Re-operation
Jakob <i>et al.</i> ¹	18 (19)	Neer: 81	14 satisfactory or excellent	5 AVN	26.3%/-	n/a
Resch <i>et al.</i> ²⁵	22	Constant: 81/84*	-	1 AVN, 1 partial AVN, 2 slight arthrosis, 1 moderate arthrosis	4.5%/4.5%	1
Resch <i>et al.</i> ²⁶	13	Constant: 82.5/87°/88*	4 excellent, 10 satisfactory, 2 unsatisfactory, 3 failures	1 displacement of lesser tuberosity, 1 partial AVN	-7.6%	1
Yu <i>et al.</i> ²²	8 (9)	Constant: 83/92.5*	All patients satisfied	no reported complications	-	-
Hockings <i>et al.</i> ²³	11	Constant: 79/86*	8 good, 2 satisfactory, 1 poor	1 AVN, 1 slight arthrosis	9%/-	-
Gerber <i>et al.</i> ²¹	8	Constant: 98	-	1 partial AVN	-12.5%	1
Panagopoulos <i>et al.</i> ²⁰	15	Constant: 87/94*	All patients satisfied	1 partial AVN	-6.6%	-
Dimakopoulos <i>et al.</i> ¹⁵	45	Constant: 89/93*	39/45 satisfied	2 partial AVN, 3 total AVN, 1 subacromial impingement, 4 HO, 1 arthritis	4.4%/6.6%	3
Atalar <i>et al.</i> ²⁸	10	Constant: 81.5	All patients satisfied	no reported complications	-	-
Keener <i>et al.</i> ¹⁷	12	Constant: 67.2 ASES: 79.9	-	1 grade 3 arthritis, 1 AVN	8.3%/-	n/a
Bogner <i>et al.</i> ²⁴	16	Constant: 49.5/68.5°/75°	13/16 very satisfied	3 AVN	18.75%/-	1
Ogawa <i>et al.</i> ²⁷	10	Constant: 85.9	-	1 impingement, 2 AVN	20%/-	-

*Constant score relative to the contralateral shoulder (%), °age- and sex adjusted Constant score. AVN, avascular necrosis; n/a, not available.

report of complications. In all included reports a unique and specified surgical technique was preferable but we included studies with mixed techniques when the majority of their cases had been performed with the less invasive of the techniques. Supplemented techniques of bone filling (graft, cement etc.) were not constituted any reason for exclusion. No Institutional Review Board (IRB) or Ethical Committee Approval is required for this type of study.

Definitions

A *prospective comparative study* was any study that collected data prospectively and compared patients with 4-part VI fractures treated with minimal invasive techniques and patients treated with a control group. A *retrospective comparative study* was similarly defined as a study in which outcomes were collected retrospectively, for example based on a clinical database. Case series was defined as a study of patients treated with minimal osteosynthesis but without a defined control intervention. The heterogeneity and level of evidence of the studies that met the inclusion criteria prevented us from performing a meta-analysis.

Results

Based on 292 database hits we identified 12 eligible studies including 190 4-part valgus impacted fractures in 188 patients treated with

LPFT (Table 1). There were no randomized, prospective or retrospective comparative studies. All eligible studies were case series composed of min 8 to max 45 patients per study.^{1,15,17,20-28} Seven studies reported solely on 4-part VI fractures,^{1,20,22,23,25,27,28} while the rest 5 studies reported mixed types of fractures including 3- and 4-part fractures without valgus impaction.^{15,17,21,24,26}

Patient demographics

The gender distribution was 60% (112) female and 40% (76) male. The average age of the patients at the time of injury was 54.5 years. In one study,²⁴ the mean age was more than 75 years representing a mixed fracture population including 2- and 3-part fractures without clarifying the mean age in VI fractures. More details of the studies are shown in Table 1. In 2 studies the loss to follow up ratio was not mentioned;^{17,24} in the remaining 10 studies (160 patients) the ratio was 6.25% (10/160).

Surgical technique

In 8/12 studies an open reduction via trans-deltoid or deltopectoral approach was used for fracture fixation with cerclage wires and/or screws,¹ KW and sutures,^{21,25} screw-wiring technique,²² and transosseous sutures.^{15,20,23,28} In one of these studies closed reduction and percutaneous fixation (CRPF) was also performed in 5/18 patients.¹

In the remaining four studies closed reduction and percutaneous fixation with KW and/or cannulated screws was used in three

papers,^{17,24,26} and intramedullary multiple pinning in one,²⁷ but in 3/10 of these patients an additional open reduction was made for tuberosity fixation. Humeral head elevation from the impacted position was performed in all studies for proper anatomic reduction except for two that proposed suturing of the head part in the valgus position to preserve the blood supply at the posteromedial hinge;^{15,20} the tuberosities were sutured below the level of the head in a tension-band manner. Filling of the metaphyseal defect was accomplished with autologous bone graft in 4 studies.^{21,22,25,28}

Clinical results

Mean follow-up time ranged from 24 to 63 months. In one study,²⁴ the mean follow up was 33.8 months and was referred to a mixed population of 3- and 4-part fractures. Four studies reported outcome using the non-adjusted Constant score, five studies used Constant Score relative to the contralateral shoulder and 2 studies used age and sex adjusted Constant Score and percentage to the contralateral shoulder (Table 2). Only Jacobs *et al.*¹ study used the Neer functional score, whereas Keener *et al.*¹⁷ used both Constant and ASES scores. Such variability limited our ability to synthesize these outcomes scores across all studies. A good Constant score (>80) was reported in 9/12 studies. The mean Neer score in Jacob's original report was also good (>80).¹

Complications

The most common complication was avascu-

lar necrosis of the humeral head with an overall incidence of 11% (range, 0-26.3%). Total AVN showed 15/188 patients (7.9%) and partial AVN 6/188 (3.1%). Two studies reported no complications at all.^{22,28} Other complications included tuberosities displacement or malunion, subacromial impingement, slight to moderate osteoarthritis, heterotopic ossification and adhesive capsulitis (Table 2). None of the studies reported any case of nerve complications and postoperative infections. The overall re-operation rate was very low (3.7%).

Discussion

As the incidence of proximal humeral fractures continues to increase, the ability to identify specific fracture patterns is critical to provide appropriate care. The clinical studies reporting the outcome of LPFT in 4-part VI fractures of proximal humerus are few, based on retrospective study designs, and often unclearly reported. We are unaware of any previously published systematic review of a similar nature. A considerable risk of biases can be attributed to fracture classification and inadequate radiological control, mean age of patients, non-adjusted clinical outcome, mixed types of surgical techniques and fixation methods, and small follow up periods. These factors should be analyzed further in detail.

Classification and radiological control

The interpretation of data from clinical trials of proximal humeral fractures is impeded by the use of 2 partly dissimilar fracture classification systems, Neer and AO/OTA. Brorson *et al.*²⁹ analyzed 10 studies with 2530 pairs of data on proximal humeral fractures classified according to both systems and found 35% *not plausible* and 34% *problematic* combinations. The 4-part valgus impacted fracture pattern can be regarded a *precursor* to the *classical* 4-part fracture (Neer group 12). In the AO/OTA classification only the types *C1.1* and *C2.1* represent the 4-part valgus impacted fracture according to Neer classification; the valgus rotation of the articular segment is slight in type *C1.1* and marked in type *C2.1*. Several studies have shown low reproducibility and reliability of both classification systems, especially when 3- or 4-part fractures were assessed by means of plain radiographs.^{30,31} In contrast, Tamai *et al.*³² have shown in a retrospective review of 509 fractures that 501 (98%) of them had an appropriate category in the revised Neer classification. The incidence of 4-part VI fracture in this study was 3.3% (17/509 fractures) which is significant lower than the 14% (99/730 fractures) in Jacobs original report.¹ The authors suggested also that the characterization of a fracture as 4-part valgus-

impacted has to meet all of the following 4 requirements: i) the humeral head is impacted into the shaft, ii) the humeral head and the glenoid fossa are in some contact, iii) the tuberosities are fractured but remain near the humeral head and shaft, and iv) the medial part of the humeral head is in some contact with the medial part of the proximal shaft. In the present review 7/12 studies were referred solely to 4-part VI fractures whereas in the other 5 studies data were extracted from a mixed population of fractures including 3- and 4-part fractures. It remains difficult to interpret and generalize results, to conduct prognostic studies, and to obtain consensus on treatment recommendations, if there is not a universal classification system of fracture pattern. As the 4-part VI fractures are unique and present special characteristics and prognosis we recommend the use of the revised Neer's classification in future studies with the inclusion of the specific criteria reported by Tamai *et al.*³² Another important issue is the proper radiological control. In the present review, most of the studies utilized either classical trauma series of the shoulder (AP, lateral or Y-view and axillary views) or additional AP views in external rotation and CT scans in selected cases. Nevertheless, only 2 studies from those reporting solely on 4-part VI fractures,^{20,22} provided details regarding the degree of rotation of the head fragment and the amount of its lateral displacement as well as tuberosities migration. In future studies, when a mixed population of proximal humeral fractures is presented, clarification of 4-part VI characteristics (age, radiological criteria with CT confirmation, outcome and complications) is essential as many studies in this review were excluded because they had no reported separate data for this category.

Mean age of patients

The relatively low mean age in the included studies (mean, 54.5 years-old) may indicate an unreported upper limit of age for use of minimal invasive surgical techniques. If that is the case the reported outcomes cannot be used as a basis for clinical decision making in the very elderly. Only the study of Bogner *et al.*²⁴ reported outcomes in patients over 70 years old after Humerus block percutaneous fixation in both 3- and 4-part fractures. Although the absolute Constant score for the 4-part fractures was very low (49.5), the same score adjusted to age and gender was acceptable in contrast to other studies (68.5%). Taking into consideration the relatively younger age of patients sustained 4-part valgus impacted fractures of the proximal humerus an effort for less invasive surgical techniques and head preserving treatment is worthwhile.

Adjustment for clinical outcome

We found comparison and generalization of outcomes from the included studies problematic. It is encouraging that almost all studies (11/12) utilized the Constant score, but there are some considerations. A higher Constant Score is expected in younger patients evaluated by non-adjusted Constant Score, especially because of the weight of strength and range of motion. As non-adjusted Constant Score decreases in the very elderly the positive effect of interventions in this group is likely to be underestimated. We recommend that future clinical trials comply with the age- and sex-adjusted Constant Score proposed by Constant *et al.*³³ A questionnaire of general quality of life (*i.e.* SF-12) and overall function of the arm (*i.e.* quick-DASH) should be added also as an indicator for the prior to the fracture functional condition of the patient.

Surgical technique, length of follow up and risk of avascular necrosis

Implant selection in fixation of proximal humeral fractures should be based on the patient's age, fracture type, metaphyseal-diaphyseal comminution, bone quality, and associated injuries. Understanding also the relationship between 4-part valgus impacted fractures and the remaining blood supply is an essential, though not the sole element for decision making. Older cadaver perfusion studies of the humeral head have shown that its main arterial blood supply is via the ascending branch of the anterior circumflex humeral artery (ACHA) and its intraosseous continuation, the arcuate artery.^{34,35} More recently, however, data suggests that the contribution of the posterior circumflex humeral artery (PHCA) is more substantial than previously believed. Hettrich *et al.*³⁶ reported that the majority of the blood supply to the proximal humerus actually arises from the PHCA, which contributes up to 64% of the total humeral head perfusion. Valgus-impacted humeral head fractures universally involve fractures of both the greater and lesser tuberosities that could disrupt the blood supply from the ACHA. The articular fragment is maintained only via the postero-medial vessels that remain intact if there is minimal lateral displacement of the humeral head. Based on Hertel's criteria of humeral head ischemia,¹⁹ if the head fragment extends below the articular surface medially (metaphyseal extension) and the medial periosteal attachment is still present (intact medial hinge), as typically happens in 4-part valgus-impacted fractures, the blood supply to the humeral head could be preserved and therefore LPFT could provide a better prognosis regarding avascular necrosis.

In the present review of LPFT there was no standardized surgical approach and fixation

method. Three studies utilized closed reduction and percutaneous KW, one study intramedullary pinning fixation and 8 studies open reduction and internal fixation with sutures, wires, screws and KW; the surgical approach was transdeltoid in 3 reports, deltopectoral in 4 and both approaches were utilized in one. Three studies reported different minimal invasive techniques in the same patient population. Based on this data no consensus could be traced about the most appropriate surgical technique and approach. Interestingly no cases of infection, loosening, KW migration and neurovascular complications were reported with any of the percutaneous techniques.

The overall rate of AVN was 11% (range, 0-26.3%). When comparing ORIF to percutaneous techniques there were more cases of total AVN with the percutaneous techniques (5/51, 9.8%) in contrast to open techniques (5/114, 4.3%). A possible explanation could be the difficulty to obtain appropriate reduction by closed means in this type of fracture and furthermore to maintain this position with only KW or intramedullary wires. On the other hand partial AVN was more common in ORIF studies (5/114, 4.3%) in contrast to percutaneous techniques (1/51, 2%). A possible explanation could be the compromise of the remaining blood supply via open approaches that requires more extensive muscle and capsule detachments. Partial AVN was defined in more studies as minimal collapse or small necrotic spots of the head without significant compromise of the overall humeral head architecture. In such cases the authors reported better clinical outcomes and low re-operation rates in contrast to total AVN cases. A comparison of AVN rates between deltopectoral approach (DPA)^{21-23,28} and the less invasive deltoid splitting approach (DSA)^{15,20,25} showed unexpectedly higher rates with DSA (8.9%) in contrast to 5.4% with DPA, but this was not statistically significant. The mean follow up period was similar in both studies (DSA: 40 months *vs* DSA: 49 months) but in DSA reports there were more included patients (89 *vs* 37).

Another important issue regarding AVN is the adequate length of follow up. One recent study (Harrison *et al.*)³⁷ was excluded from this systematic review as having duplicated results and no appropriate reporting of demographic data, clinical scoring, and other complications. The authors reported in 2012 the intermediate outcome (mean 48 months, range 37-128 months) of 27 patients who were treated with closed reduction and percutaneous fixation for 2-, 3- and 4-part VI (10 cases) fractures. The short term results in 19 of them had been previously reported showing an overall rate of avascular necrosis of 8.3% for the 4-part VI fractures (12 cases).¹⁷ Re-evaluation of these patients showed unexpectedly

higher rate of osteonecrosis, especially in 4-part VI fractures (5/10 patients, 50%), as well as posttraumatic osteoarthritic changes (60%). It is possible that medical comorbidities may have contributed to the development of osteonecrosis as one of their patients had a history of Crohn disease and treatment with oral corticosteroids but for the other patients there was no identifiable alternative assumption regarding what caused the osteonecrosis. Nevertheless, only 2 of these patients required conversion to total shoulder arthroplasty, whereas the others were asymptomatic and they were detected because they were recalled for the purposes of the study. Greiner *et al.*³⁸ presented a study of 48 patients treated with stable angular plate with a mean follow-up of 45 months, and they re-assessed them after 12 months; the incidence of avascular necrosis doubled from four (8.3%) to nine (18.75%) cases, suggesting that longer follow-up is clinically relevant. Campochiaro *et al.*³⁹ reported recently a 3.7% (10/267) rate of AVN after plate-screws osteosynthesis in complex humeral fractures after an average follow-up period of 28.3±17.0 months. Only 30% of the patients in the AVN group presented all Hertel's predictors of humeral head ischemia,¹⁹ a finding that shows that not all patients presenting the most important risk factors develop finally osteonecrosis, and in some cases, the necrosis is established also without relevant risk factors. These evidence suggest that the real incidence of avascular necrosis is still unknown, maybe less than we think; some or many biological, biomechanical and/or human risk factors must be found or better understood, because the evolution in necrosis of fractures is not always correctly predictable.³⁹

The mean follow up in the reported studies was 41 months (range, 24-63) which is considered enough for reporting healing of an acute fracture. A comparison of the AVN rates between reports with shorter follow up periods,^{17,22,24-27} with those with longer follow up^{1,15,20,21,23,28} failed to demonstrate any statistical significance (overall AVN rate 10,6% *vs* 10.7%). We recommend that future clinical trials should report longer outcomes in proximal humeral fractures because osteonecrosis can happen later than 2 years, which is the proposed follow up period in the literature.

Conclusions

In this systematic review for 4-part VI fractures insufficient study designs and unclear reports preclude us from safe treatment recommendations and quantitative data synthesis of outcome. In general, least possible fixation methods could yield a good clinical outcome

with a relatively low incidence of osteonecrosis, hardware related complications and re-operation rates. One of the most important finding of this systematic review is that the overall rate of AVN was similar in both ORIF and percutaneous LPFT regardless the follow up period, the surgical approach and the fixation method. A considerable risk of biases can be attributed to several factors such as inappropriate classification of this unique fracture type, non-age adjusted clinical scoring, different methods of surgical exposure and fixation and not clear recording of demographic, clinical and radiological data when mixed populations of complex humeral fractures are reported. Well-designed randomized trials are necessary to produce a more reliable volume of data in order to provide guidelines for the management of these complex injuries.

References

- Jacob RP, Miniaci A, Anson PS, et al. Four-part valgus impacted fractures of the proximal humerus. *J Bone Joint Surg Br* 1991;73:295-8.
- De Anquin CE, de Anquin CA. Prosthetic replacement in the treatment of serious fractures of the proximal humerus. *Shoulder surgery*. Berlin: Springer-Verlag; 1982:207-217.
- Stableforth PG. Four-part fractures of the neck of the humerus. *J Bone Joint Surg* 1984;66B:104-8.
- Neer CS. Displaced proximal humeral fractures. I. Classification and evaluation. *J Bone Joint Surg Am* 1970;52:1077-89.
- Müller ME, Nazarian S, Koch P, Schatzker J. The comprehensive classification of fractures of long bones. Berlin: Springer; 1990.
- Marsh JL, Slongo TF, Agel J, et al. Fracture and dislocation classification compendium - 2007: Orthopaedic Trauma Association classification, database and outcomes committee. *J Orthop Trauma* 2007;21:S1-133.
- Neer CS II. Four segment classification of proximal humeral fractures: Purpose and reliable use. *J Shoulder Elbow Surg* 2002;11:389-99.
- Harvie P, El-Guindi M. Four-part valgus impacted proximal humeral fracture presenting three months after injury in a young patient: open reduction and internal fixation with triple osteotomy and bone graft augmentation. *J Shoulder Elbow Surg* 2009;18:e4-8.
- Court-Brown CM, Cattermole H, McQueen MM. Impacted valgus fractures (B1.1) of the proximal humerus. The results of non-operative treatment. *J Bone Joint Surg Br*

- 2002;84:504-8.
10. Robinson CM, Longino D, Murray IR, Duckworth AD. Proximal humerus fractures with valgus deformity of the humeral head: the spectrum of injury, clinical assessment and treatment. *J Shoulder Elbow Surg* 2010;19:1105-14.
 11. Maier D, Jaeger M, Izadpanah K, et al. Proximal humeral fracture treatment in adults. *J Bone Joint Surg Am* 2014;96:251-61.
 12. Thanasis C, Kontakis G, Angoules A, et al. Treatment of proximal humerus fractures with locking plates: a systematic review. *J Shoulder Elbow Surg* 2009;18:837-44.
 13. Sproul RC, Iyengar JJ, Devcic Z, Feeley BT. A systematic review of locking plate fixation of proximal humerus fractures. *Injury* 2011;42:408-13.
 14. Brorson S, Rasmussen JV, Frich LH, et al. Benefits and harms of locking plate osteosynthesis in intraarticular (OTA Type C) fractures of the proximal humerus: a systematic review. *Injury* 2012;43:999-1005.
 15. Dimakopoulos P, Panagopoulos A, Kasimatis G. Transosseous suture fixation of proximal humeral fractures. *J Bone Joint Surg Am* 2007;89:1700-9.
 16. Resch H, Hübner C, Schwaiger R. Minimally invasive reduction and osteosynthesis of articular fractures of the humeral head. *Injury* 2001;32:SA25-32.
 17. Keener JD, Parsons BO, Flatow EL, et al. Outcomes after percutaneous reduction and fixation of proximal humeral fractures. *J Shoulder Elbow Surg* 2007;16:330-8.
 18. Robinson CM, Page RS. Severely impacted valgus proximal humeral fractures. Results of operative treatment. *J Bone Joint Surg Am* 2003;85A:1647-55.
 19. Hertel R, Hempfing A, Stiehler M, Leunig M. Predictors of humeral head ischemia after intracapsular fracture of the proximal humerus. *J Shoulder Elbow Surg* 2004;13:427-33.
 20. Panagopoulos AM, Dimakopoulos P, Tyllianakis M, et al. Valgus impacted proximal humeral fractures and their blood supply after transosseous suturing. *Int Orthop* 2004;28:333-7.
 21. Gerber C, Werner CM, Vienne P. Internal fixation of complex fractures of the proximal humerus. *J Bone Joint Surg Br* 2004;86:848-55.
 22. Yu KS, Chan PT, Lau SC, et al. Internal fixation of valgus-impacted humeral head fractures using the screw-wiring technique. *Int Orthop* 2002;26:13-6.
 23. Hockings M, Haines JF. Least possible fixation of fractures of the proximal humerus. *Injury* 2003;34:443-7.
 24. Bogner R, Hübner C, Matis N, et al. Minimally-invasive treatment of three- and four-part fractures of the proximal humerus in elderly patients. *J Bone Joint Surg Br* 2008;90:1602-7.
 25. Resch H, Beck E, Bayley I. Reconstruction of the valgus-impacted humeral head fracture. *J Shoulder Elbow Surg* 1995;4:73-80.
 26. Resch H, Povacz P, Fröhlich R, Wambacher M. Percutaneous fixation of three- and four-part fractures of the proximal humerus. *J Bone Joint Surg Br* 1997;79:295-300.
 27. Ogawa K, Kobayashi S, Ikegami H. Retrograde intramedullary multiple pinning through the deltoid "V" for valgus-impacted four-part fractures of the proximal humerus. *J Trauma* 2011;71:238-44.
 28. Atalar AC, Demirhan M, Uysal M, Seyahi A. Treatment of Neer type 4 impacted valgus fractures of the proximal humerus with open reduction, elevation, and grafting. *Acta Orthop Traumatol Turc* 2007;41:113-9.
 29. Brorson S, Eckardt H, Audigé L, et al. Translation between the Neer- and the AO/OTA-classification for proximal humeral fractures: do we need to be bilingual to interpret the scientific literature? *BMC Res Notes* 2013;6:69.
 30. Brorson S, Bagger J, Sylvest A, Hrobjartsson A. Diagnosing displaced four-part fractures of the proximal humerus: a review of observer studies. *Int Orthop* 2009;33:323-7.
 31. Gumina S, Giannicola G, Albino P, et al. Comparison between two classifications of humeral head fractures: Neer and AO-ASIF. *Acta Orthop Belg* 2011;77:751-7.
 32. Tamai K, Ishige N, Kuroda S, et al. Four-segment classification of proximal humeral fractures revisited: a multicenter study on 509 cases. *Shoulder Elbow Surg* 2009;18:845-50.
 33. Constant CR, Gerber C, Emery RJ, et al. A review of the Constant score: modifications and guidelines for its use. *J Shoulder Elbow Surg* 2008;17:355-61.
 34. Laing PG. The arterial supply to the adult humerus. *J Bone Joint Surg Am* 1956;38A:1105-16.
 35. Gerber C, Schneeberger AG, Vinh TS. The arterial vasculisation of the humeral head: an anatomical study. *J Bone Joint Surg Am* 1990;72A:1486-94.
 36. Hettrich CM, Boraiah S, Dyke JP, et al. Quantitative assessment of the vascularity of the proximal part of the humerus. *J Bone Joint Surg Am* 2010;92:943-8.
 37. Harrison AK, Gruson KI, Zmistowski B, et al. Intermediate outcomes following percutaneous fixation of proximal humeral fractures. *J Bone Joint Surg Am* 2012;94:1223-8.
 38. Greiner S, Kaab MJ, Haas NP, Bail HJ. Humeral head necrosis rate at mid-term follow-up after open reduction and angular stable plate fixation for proximal humeral fractures. *Injury* 2009;40:186-91.
 39. Campochiaro G, Rebuzzi M, Baudi P,