

A. X. Papadopoulos  
A. Karabasi  
A. Panagopoulos  
A. Karageorgos  
M. Papas  
E. Lambiris

## Secondary Intramedullary Nailing for the Treatment of Complications after Bone Lengthening

### Abstract

Thirty patients (33 cases) underwent a secondary intramedullary nailing during the consolidation phase after callus distraction with an external device. Docking site non-union (17 patients), angular deformity or fracture of the lengthened area (8 patients) and intolerance of the external device (5 patients), in combination or not with a delayed distracted callus maturation, were the main indications for this replacement. The femur was involved in 13 cases and the tibia in 20. One-stage intramedullary nailing conversion was done in 25 cases and a delayed procedure in 8 cases. The average follow-up period was 4 years (2–12 years). Deep infection was presented in one case (3.03%) and slight callus length loss in 5 cases (15.2%). Failure of union at the docking site and breakage of the nail was noted in 1 case (3.03%). In the rest of the patients, solid union was achieved in the lengthened callus area as well as at the docking site, in an average period of 5.9 months after the modification. All patients were quite satisfied as their functional improvement was rapidly accelerated. The use of intramedullary nailing during the consolidation phase after callus distraction is a treatment option for delayed callus maturation or docking site non-union, thus reducing the prolonged use of the external fixator.

### Key words

Secondary intramedullary nailing · distraction osteogenesis · bone lengthening

### Introduction

Distraction osteogenesis has been proved a powerful clinical tool in treating patients with a variety of skeletal problems. The method addresses successfully many indications such as infections, bone defects, deformities, and leg-length discrepancies. Practice of the method in difficult cases was often associated with high rate of complications, mostly related to the prolonged time of application [2, 5, 6, 16]. The required time is sometimes too long so that discomfort for the patient becomes greater than we expect. To these subjective complaints we must also add the common problems of pin-track infection and joint rigidity that have forced us to remove the elongation-stabilisation device in a premature phase, when the lengthened callus has not yet been consolidated. This early removal may lead to serious complications such as plastic deformity of the callus, axial deviation, fracture, shortening and loss of the so far achieved isoskelia.

Another fundamental aspect is the potential non-union at the docking site after bone transport. This complication is frequent, particularly in cases with large post-traumatic bone defects, as the poor soft tissue coverage, reduced vascularisation and possible interference of connective tissue among bone ends do not offer good healing conditions in this particular region. In high-energy trauma also, with bone comminution, the transferred bone ends may not have enough contact or stability during the time of compression.

The aim of this study is to present our clinical experience in the use of intramedullary nailing during the consolidation phase

Department of Orthopaedic Surgery, Patras University, Patras University Medical Center, Rio-Patras, Greece

### Affiliation

Andreas X. Papadopoulos · Orthopaedic Department of Patras University Hospital · Papanikolaou st. 1 · 26504 Rio-Patras · Greece · Phone: +30/26 10-999-555 · Fax: +30/26 10-994-579 · E-mail: paprod@hotmail.com

### Correspondence

### Bibliography

Osteo Trauma Care 2004; 12: 145–150 © Georg Thieme Verlag KG Stuttgart · New York  
DOI 10.1055/s-2004-822826  
ISSN 1618-971X

after bone lengthening or bone transport for a) further stabilisation of the lengthened callus, b) enhancement of callus maturation and c) docking site union.

## Patients and Methods

Between 1990 and 2001, among 230 patients who were treated with distraction osteogenesis with an external device (Ilizarov frame or unilateral system) in our institution, 30 patients (33 cases) underwent secondary intramedullary nailing during the consolidation phase. There were 4 females and 26 males, aged 12–68 years (average 30.4 years). The femur was involved in 13 cases and the tibia in 20 (3 patients had 2 bones involved at the same time). The lengthening procedure was needed because of 6 septic non-unions, 10 leg-length discrepancies, 8 post-traumatic bone defects (accompanied with soft tissue defects), 2 peroneal hemimelias, 4 non-septic non-unions and 3 cases of chronic osteomyelitis. The lengthening distance varied from 2 to 28 cm (average 7.4 cm). The main reasons for exchanging the external lengthening device to intramedullary nailing were the delay in union at the docking site (17 patients), the patient's discomfort due to the prolonged use of the device (5 patients) and the angular deformity ( $>10^\circ$ ) or the fracture of callus in the lengthened area (8 patients) in combination with the delayed maturity of the distracted callus in some of these cases.

Essential qualification for the modification of the method into intramedullary nailing was the integration of bone lengthening and compensation of soft tissues. All soft tissue defects had been already treated either with distraction histogenesis or with muscle flaps or skin grafts. Moreover, the absence of clinical and haematological signs of infection was essential: all of the patients had a normal white blood-cell count, erythrocyte sedimentation rate and C-reactive protein and were free of clinical signs of infection (even pin-track infections) when the nailing was performed.

In 25 cases, the nail was applied as soon as the Ilizarov frame was removed. In 5 cases with unilateral lengthening systems the nailing was postponed for approximately 2 weeks to accommodate pin-track healing and a long leg plaster was used for temporary immobilisation. In 3 patients the nailing was performed because of a fracture of the callus some days or weeks after the removal of the external device.

## Operative technique (Figs. 1 and 2)

The patient was placed in a traction table to insure the normal axis of the lengthened callus during removal of Ilizarov frame and application of the intramedullary nail. The next step was the meticulous sterilisation of the skin, frames and transosseous pins as well as infusion of povidone iodine (Betadine) into the skin holes after the removal of the Ilizarov device. Then, using the standard intramedullary entry points in the femur or tibia, a guide wire was passed through the lengthened area under C-arm image intensifier guidance. If the callus was quite soft the introduction of the guide wire through the lengthened area into the

distal part of the bone was easy. In the opposite case where, either the callus of the lengthened area was too hard or the bone ends at the docking site were incongruent, the passage of the guide wire was obstructed and in these cases the canal was opened by a long, straight and hard awl, which was introduced carefully under C-arm guidance. Nail application followed after limited reaming of both the intramedullary canal and the callus area. The usual diameter of the femoral nail was 12 mm and of tibia not more than 10 mm. All patients received 4 doses of prophylactic antibiotic therapy with a 2<sup>nd</sup> generation cephalosporin and low-molecular heparin for 6 weeks postoperatively.

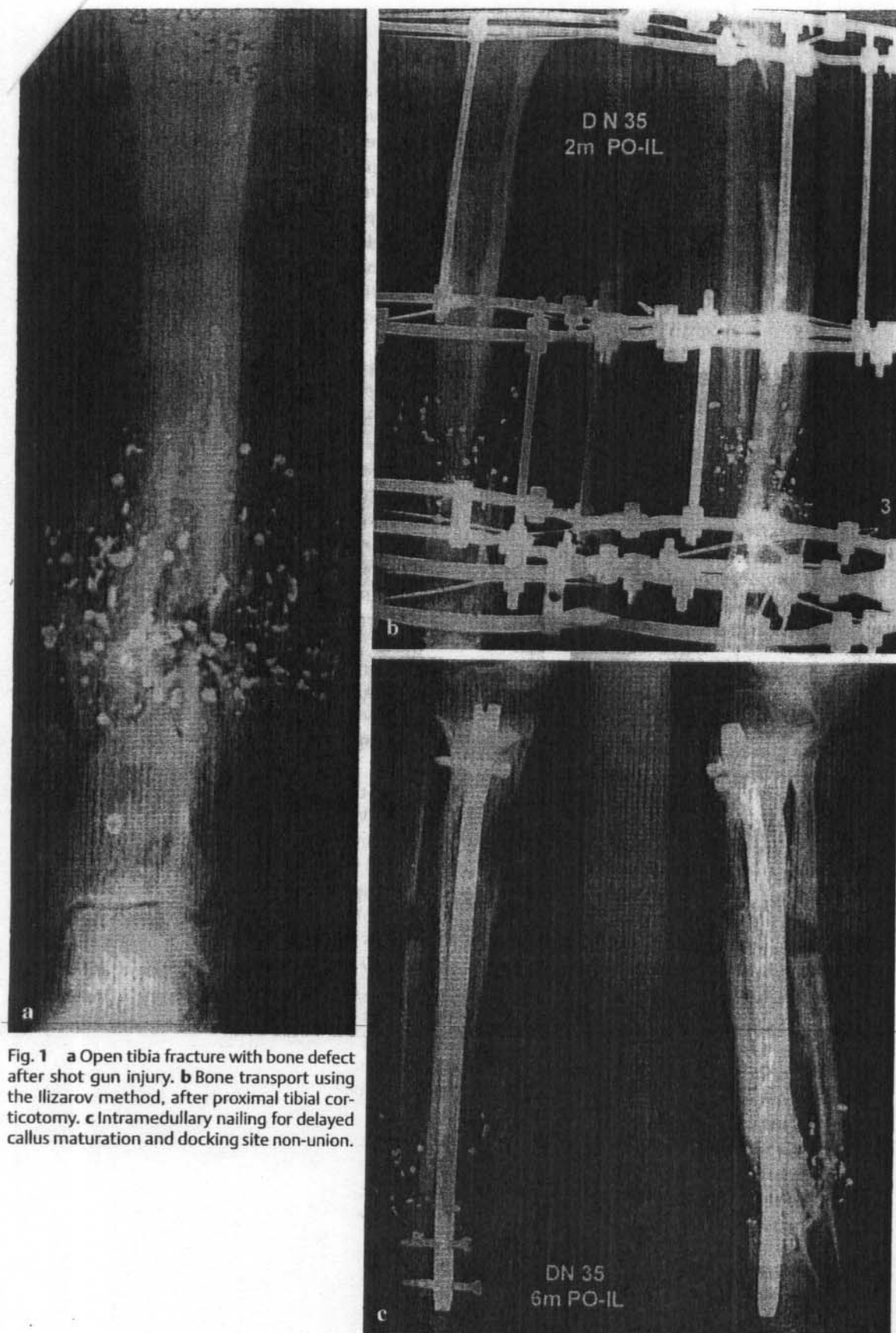
## Results

The average follow-up period was 4 years (2–12 years). The average external fixation index was 38 days per cm of distraction. All the patients were satisfied after the removal of the external device as their joint mobility and overall functional improvement was accelerated.

In one case, with three-centimetres bone loss after a supracondylar fracture, docking site non-union remained unhealed after intramedullary nailing. In particular, the nail was broken 3 years after implantation and a new frame fixator was used. Ten of the docking site non-unions (58.8%) led to solid callus formation within six months after nail insertion. The remaining 6 cases (35.3%) had a delayed progress of union but no clinical symptoms. Dynamisation of 3 static nails was performed 8 weeks postoperatively, when the maturation of the lengthened area had been completed to accommodate the healing process at the docking site. In no case was bone grafting used. Deep infection was detected in one patient (3.03%) and was finally treated with nail removal and external fixator reapplication. In 5 cases (patients 5, 8, 24, 28, 29) there was a 1–2 cm shortening of the callus. All patients were satisfied (objective questionnaire) after the removal of the external fixator as their joint mobility was improved rapidly and they could take part in the daily living activities without carrying the bulky transosseous system any more. Skin and soft tissue condition was also improved after the removal of the transosseous pins.

## Discussion

The basic principles of distraction osteogenesis, as they have been described by G. Ilizarov are: a) the progressive bone distraction, b) the symmetrical distribution of distraction by a stable ring external fixator and c) the preservation of periosteal and intramedullary vessels through the corticotomy. These suitable biological and mechanical conditions transform the progressive irritation of the distraction into biological reaction. Expressions of this reaction are the increased vascularisation, the presence of membranous ossification, as well as the phenomenon of "growth plate", which refers to the embryonic stage of bone activation [3, 9, 10]. Recent studies have shown that, in contrast to lengthening that initiated from a central area (growth plate), the periosteum plays the more important role for the growth and maturation of the callus than the bone marrow and endosteum [8, 12]. The capabilities of this method are impressive, in



**Fig. 1** **a** Open tibia fracture with bone defect after shot gun injury. **b** Bone transport using the Ilizarov method, after proximal tibial corticotomy. **c** Intramedullary nailing for delayed callus maturation and docking site non-union.

**Fig. 1d** ►

particular in cases of congenital length discrepancies and large bone defects.

On the other hand, the biological and mechanical environment that is created after intramedullary nailing seems to be particu-

larly beneficial to resolve problems that become apparent during the osteogenesis process. One major problem is the patient's discomfort from the long-standing application of the external device and, on the other hand, the biomechanical failures such as the axial deviation, the fracture of the lengthened area, the de-



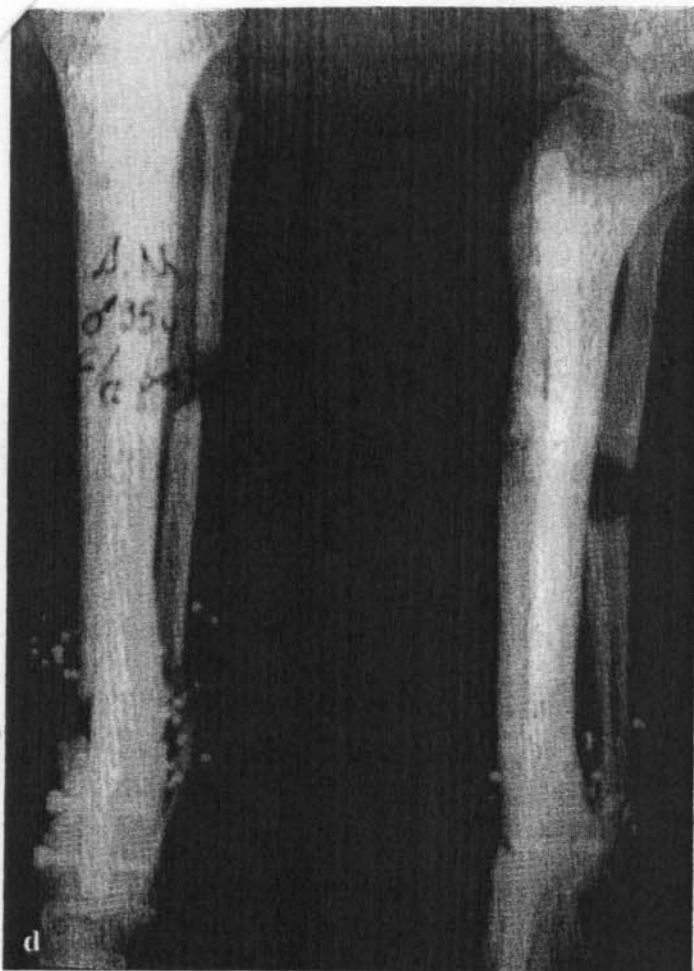

Fig. 1d Ossification of the callus and docking site union, 6 months after the nail application.

lay of callus maturation and the non-union at the docking site after the integration of bone transfer. The repeated modifications of external fixator, the prolonged duration of lengthening, the use of bone grafting or other local interventions to improve the biological conditions in the lengthened or docking site area are not adequate measurements in the majority of cases.

Under these circumstances, in those cases where an additional stabilisation of the lengthening callus or an enhancement of the biological environment for callus growth or union at the docking side was considered necessary, we convert our technique to intramedullary nailing [13, 17, 19]. The functional, emotional and psychological status of our patients was improved immediately after fixator removal, especially in those cases with prolonged time of application (up to 2 years). They were able to take care of themselves and perform their daily-living activities much more easily. Skin and soft tissues condition was also improved in addition to the increased level of adjacent joints mobility, which were already stiff due to the prolonged time of immobilisation.

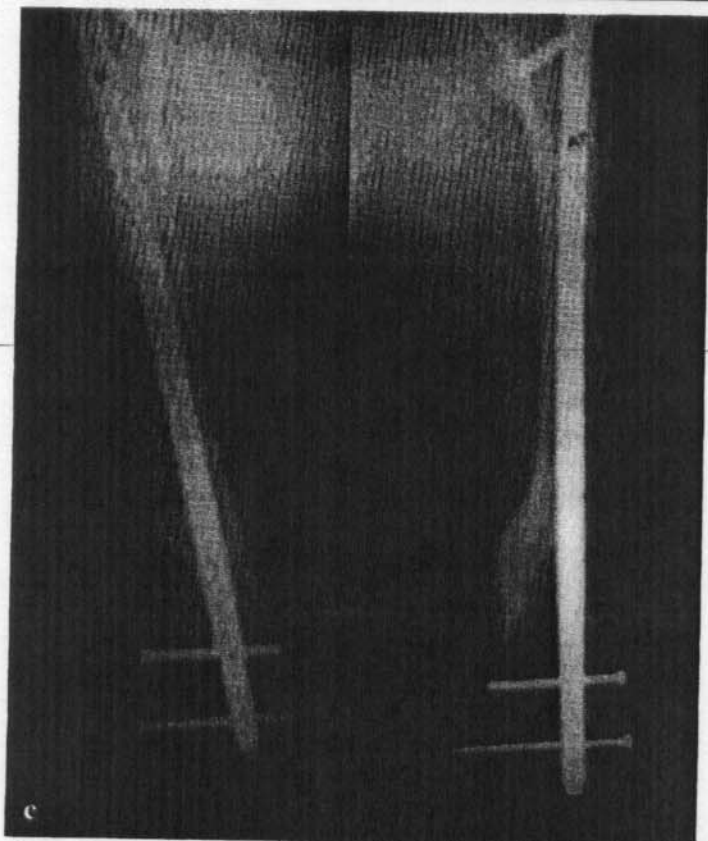
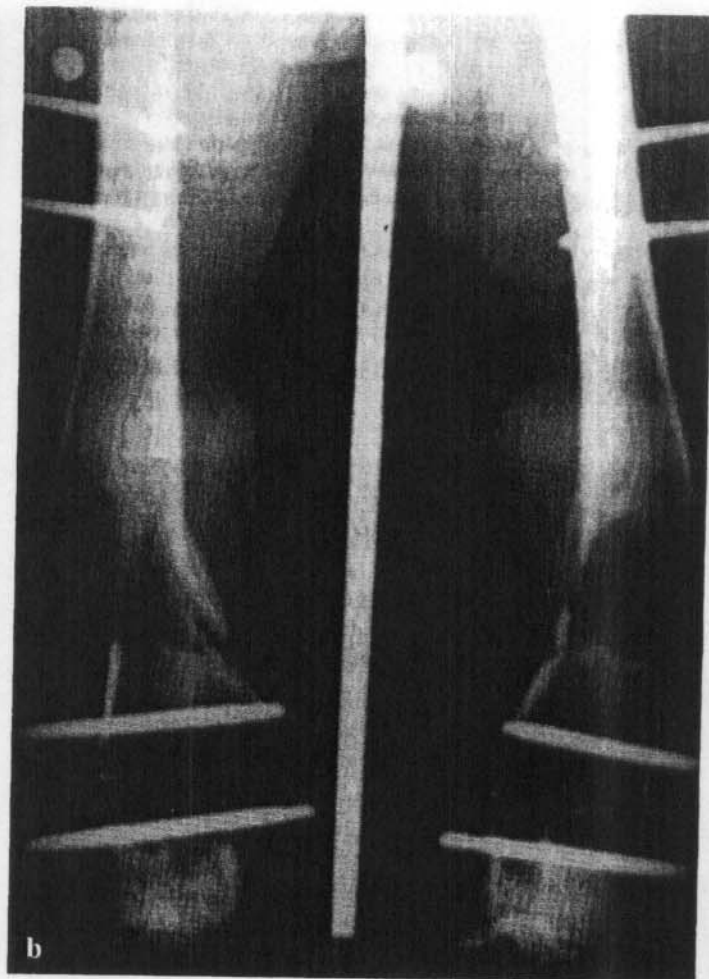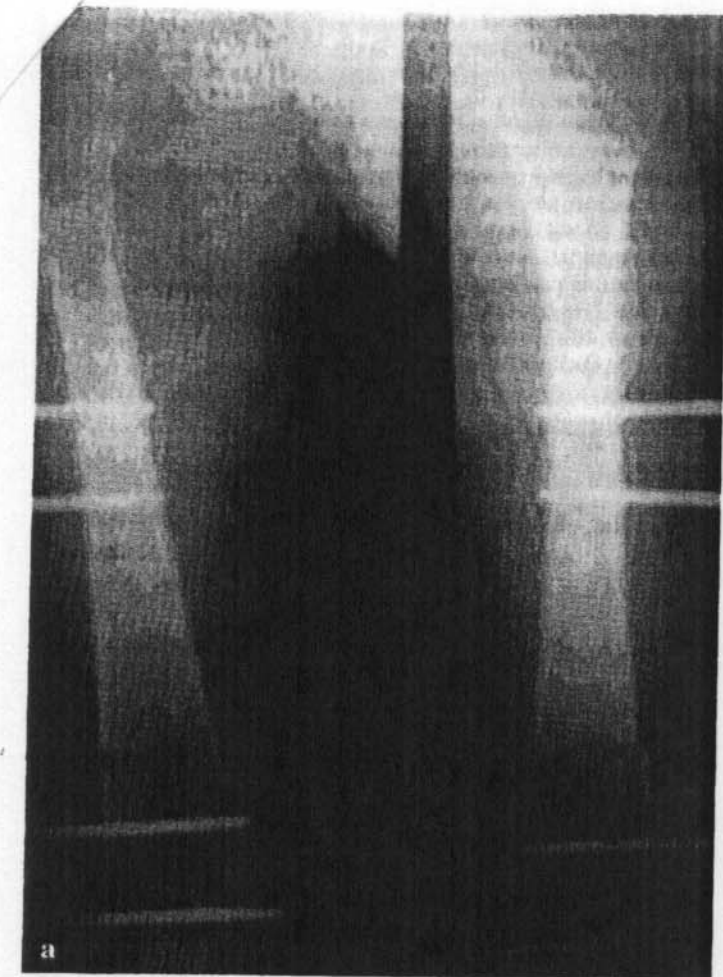
Another important fact was that in all patients the union progress at the lengthening area was accelerated without any disturbances in relation to the length and linearity of the callus. It is worth noting that there was a well-marked sub-periosteal ossification in plain radiographs.

Secondary intramedullary nailing after distraction osteogenesis requires some major considerations, with the majority of them concerning the lack of intramedullary blood supply and the stability of the neo-formed callus. The neo-angiogenetic capability of intramedullary vessels after reamed intramedullary nailing is quite high and reversible within 2–4 weeks [7, 15]. It is also well known that reaming enhances the topical congestive reaction, lasting for 2–4 weeks, followed by centripetal re-vascularisation of the cortex from the periosteal vessels [18]. In conclusion, closed intramedullary nailing as a biological method of fixation, not only leaves the periosteum intact in such a way that the immature callus can be ossified but also adds a new osteoinductive environment through the congestive reaction.

Intramedullary nailing resolves also the potential complications at the docking site area. Freshening of the bone ends, removal of the atrophic connective tissue, bone grafting and stable fixation can all be ensured with the application of a nail: intramedullary reaming freshening bone ends and destroying the connective tissue which may be intervening between them. Reaming products have osteoinductive properties, acting as bone grafting whereas the congestive reaction improves the poor conditions of blood supply at the docking site area. Finally, the choice of static intramedullary nailing gives the appropriate stability and the possibility to convert it into the dynamic one when the callus has been ossified.

Another important consideration is the possibility of deep intramedullary infection [1, 4, 11, 14, 20]. Our indications for modification of external fixation to intramedullary nailing included the integration of bone lengthening or bone transfer, restoration of skin and soft tissues impairment, and the absence of clinical signs of infection (both general and local such as pin irritation and normal values of WBC, SER and CRP). If there was any suspicious area of infection, a culture was obtained from the entry holes of the pins. Under these conditions we believe that the replacement of the external fixator with intramedullary nailing using the common modes (i.e., 2<sup>nd</sup> generation cephalosporin) and doses of peri-operative prophylactic antibiotics, is a safe procedure. As the Ilizarov pins are not threaded and have small diameters, their removal, except if there were positive signs of infection, can be followed by application of the nail as a one-stage procedure preserving the shape of the callus and the patient from another operation. In cases in which threaded, larger diameter pins have been used, we propose the delay of nail application in accordance to the results of cultures: if there are negative the nail was applied within 10 days otherwise in case of positive cultures after a period of 6 weeks in which the patient is covered with the appropriate antibiotic therapy. During this period the callus must be protected with cast.

In conclusion, we believe that distraction osteogenesis is a unique method for resolving difficult orthopaedic problems but, in selected cases, its conversion to intramedullary nailing after the integration of bone lengthening or transfer has major indications such as: the relief of patient from the bulky external fixator, the protection of callus from axial deformities, the enhancement of union at the docking site and the retrieval of joint mobility and function. In a few words we can say that intramedullary nailing concludes our therapy and re-activates the principles of distractive osteogenesis.



**Fig. 2** **a** Bilateral distal femur corticotomy for femoral lengthening using unilateral external fixators (braxisomia). **b** Angular deformity of the calluses. **c** Secondary interlocking nailing for correction of the deformities.

## References

- <sup>1</sup> Antich-Adrover P, Marti-Garin D, Murias-Alvarez J, Puente-Alosa C. External fixation and secondary intramedullary nailing of open tibial fractures: a randomized, prospective trial. *J Bone Joint Surg [Br]* 1997; 79: 433–437
- <sup>2</sup> Aquerreta JD, Forriol F, Canadell J. Complications of bone lengthening. *Internat Orthop* 1994; 18: 299–303
- <sup>3</sup> Aronson J, Good B, Stewart C, Harrison H. Preliminary studies of mineralization during distraction osteogenesis. *Clin Orthop* 1990; 250: 43–49
- <sup>4</sup> Blachut PA, Meek RN, O'Brien PT. External fixation and delayed intramedullary nailing of open fractures of the tibial shaft: a sequential protocol. *J Bone Joint Surg [Am]* 1990; 72: 729–735
- <sup>5</sup> Dahl MT, Gulli B, Gerg T. Complications of limb lengthening. *Clin Orthop* 1994; 301: 10–18
- <sup>6</sup> Fischgrund J, Paley D, Suter C. Variables affecting time to bone healing during limb lengthening. *Clin Orthop* 1994; 301: 31–37
- <sup>7</sup> Grundnes O, Utvag SE, Reikeras O. Effects of graded reaming on fracture healing. Blood flow and healing studied in rat femurs. *Acta Orthop Scand* 1994; 65: 32–36
- <sup>8</sup> Guichet JM, Braillon P, Bodenreider O, Lascombes P. Periosteum and bone marrow in bone lengthening. A DEXA quantitative evaluation in rabbits. *Acta Orthop Scand* 1998; 69: 527–531
- <sup>9</sup> Ilizarov GA. The principles of the Ilizarov method. *Bull Hosp Joint Dis* 1988; 48: 1–11
- <sup>10</sup> Ilizarov GA. Clinical application of the tension-stress effect for limb lengthening. *Clin Orthop* 1990; 250: 8–26
- <sup>11</sup> Johnson EE, Simpson LA, Helfet DL. Delayed intramedullary nailing after failed external fixation of the tibia. *Clin Orthop* 1990; 253: 251
- <sup>12</sup> Kojimoto H, Yasui N, Goto T. Bone lengthening in rabbits by callus distraction: The role of periosteum and endosteum. *J Bone Joint Surg [Br]* 1988; 70: 543–549