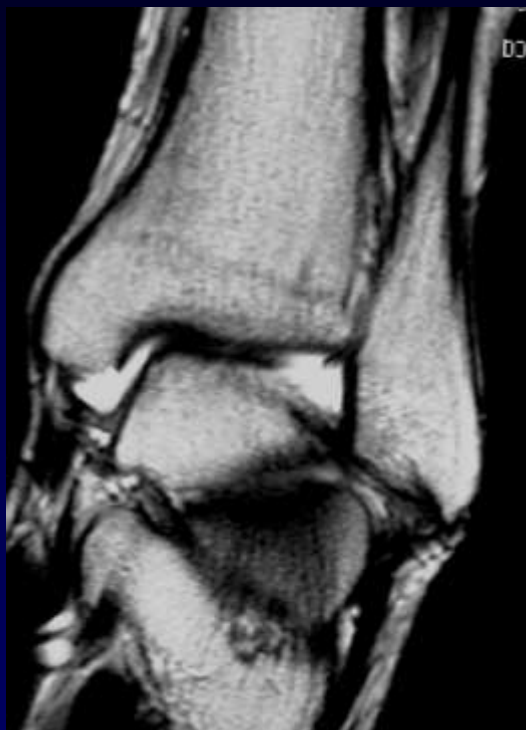

# CORRELATION OF CLINICAL, RADIOLOGICAL AND ARTHROSCOPIC FINDINGS IN POST-TRAUMATIC INSTABILITY OF THE ANKLE JOINT: THE CRITICAL ROLE OF THE CALCANEOFIBULAR LIGAMENT



A. Panagopoulos, MD, PhD  
Clinical Research Fellow

V. Kumar, MRCS (Glas)  
SHO in Orthopaedics

J. Triantafyllopoulos, MD, PhD  
Clinical Research Fellow

S. Fitzgerald, FRCR, MRCP (Irl)  
Consultant Radiologist

L. van Niekerk, MD, FRCS (Ed), FRCS (Orth)  
Consultant Orthopaedic Surgeon



**Sports Orthopaedic Centre, Friarage Hospital  
& Duchess of Kent Military Hospital,  
Northallerton, North Yorkshire, United Kingdom**

# Natural history - prognosis

- 80% to 85% of acute ankle sprains are successfully treated with a functional ankle-rehabilitation program<sup>1</sup>
- The remaining 15% to 20% have recurrent ankle instability and re-injury, necessitating surgical intervention<sup>2</sup>
- 25% to 95% incidence of chondral lesions<sup>3</sup> (persistent pain after ligament reconstruction)
- degenerative changes after 10 years in patients with chronic ankle instability



1. Baumhauer J et al. Journal of Athletic Training, 2002

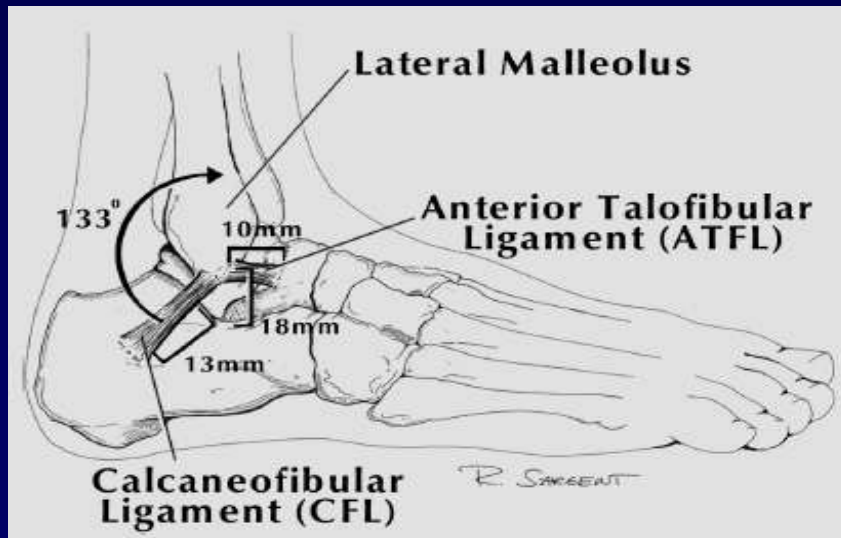
2. Colville MR, et al. Am J Sports Med, 1990

3. Hintermann B et al. Am J Sports Med, 2002

4. Harrington KD et al. JBJS Am, 1979

# Anatomy

- **ATFL** is the primary restraint to inversion and is usually torn in inversion, plantar flexion and internal rotation<sup>1</sup>
- **CFL** stabilizes both the ankle & subtalar joint and tears primarily in inversion and ankle dorsiflexion<sup>1</sup>
- In a cadaveric study ATFL was always torn when CFL was torn



1. Burks RT and Morgan J. *Am J Sports Med*, 1994
2. Heilman AE et al. *Foot Ankle*, 1990
3. Rasmussen O. *Acta Orthop Scand Supl*, 1985

## “types of instability”

- ATFL # functional instability → arthroscopy  
(giving way symptoms)
- CFL # mechanical instability → reconstruction  
(positive provocative tests)

Baumhauer and O'Brien. *J Athl Train*, 2002

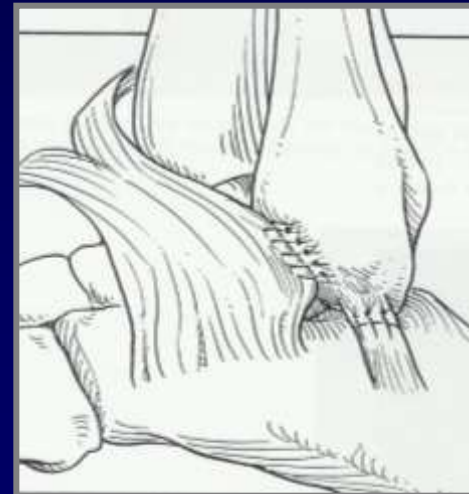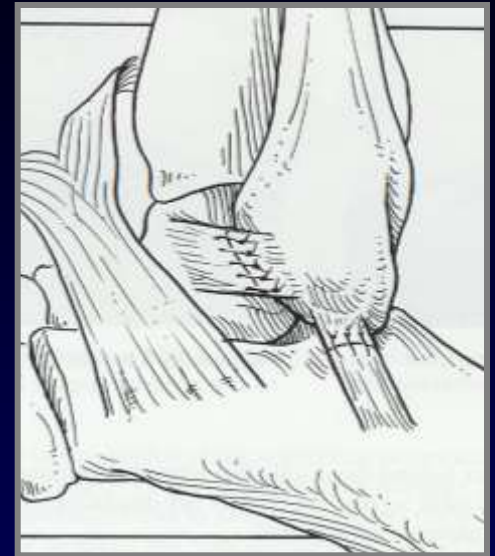Peronei # → proprioception → repair

Karlsson J, et al. *J Athl Train*, 2002

# Surgical treatment

## Anatomic repair

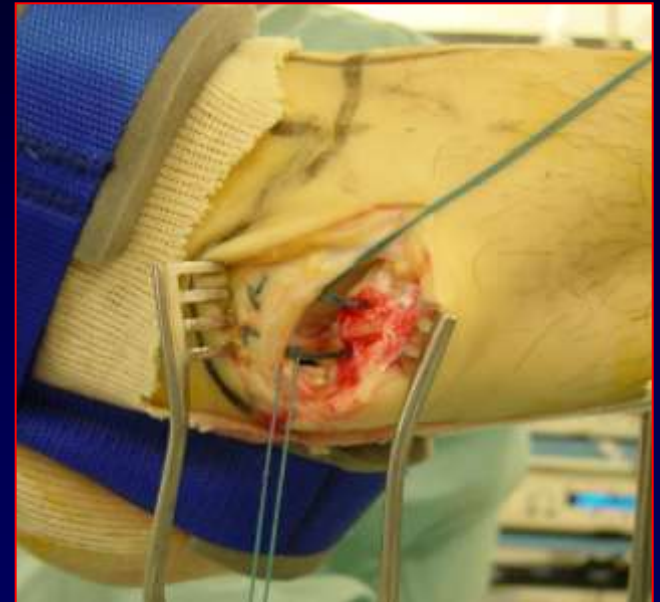- Bostrom (95%)
- Gould et al (85-90%)
- Karlsson et al (80%)



1. Brostrom L. *Acta Chir Scand*, 1966
2. Gould N, et al. *Foot Ankle*, 1980
3. Karlsson J et al *Am J Sports Med.*, 1989

# Bostrom - Could modification

- ✓ 85%-95% success rate
- ✓ Increased stability
- ✓ Preserves subtalar & talo-crural motion
- ✓ Fewer associated nerve injuries
- ✓ Less morbidity
- ✓ Quicker functional recovery
- ✓ No proprioception interference



Krips R, et al. *Foot Ankle Int*, 2001

Matsusaka N, et al. *Am J Sports Med*, 2001

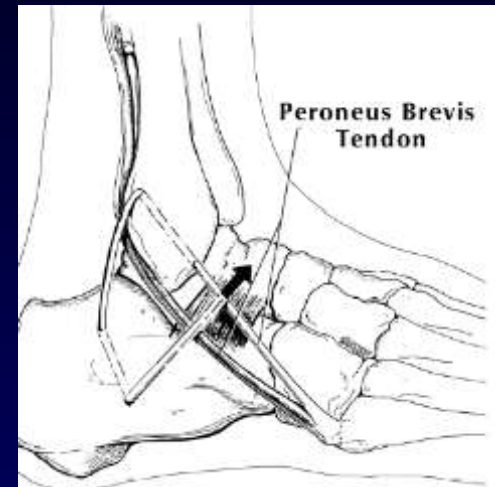
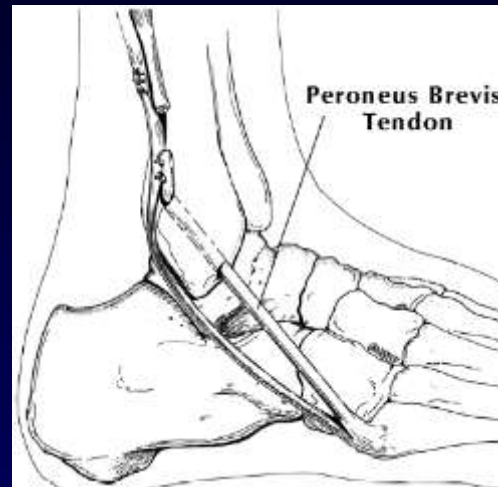
Hennrikus WL, *Am J Sports Med*, 1996



# Surgical treatment

## Ligament reconstruction

- Evans
- Crisnman-Snook
- Leach
- Watson-Jones
- Larsson
- Karlsson
- Colville



1. Snook GA, & Chrisman OD. *J Bone Joint Surg Am*, 1985
2. Leach RE, et al. *Clin Orthop*, 1981

# Clinical comparison

## Anatomic procedures vice Ligament reconstruction

- **Karlsson** (2-10 year follow-up in a multicenter trial) : Tenodeses did not restore normal anatomy of the lateral ankle ligaments, unlike the anatomic repairs (restricted range of motion, reduced long-term stability and increased risk of medial degenerative joint disease)
- **Hennrikus** demonstrated that the modified Brostrom procedure resulted in higher patient satisfaction. In addition, a greater proportion of complications occurred with the Chrisman-Snook procedure
- **Liu** showed that biomechanically, the modified Brostrom procedure was associated with less anterior talar displacement and a decreased talar-tilt angle compared with the Chrisman-Snook procedure



# Ankle instability hypothesis

- Only unstable ankles with ligament rupture (mechanical instability) require reconstruction
- Functional instability can be improved with arthroscopic treatment of the ankle
- Mechanical stability is not lost with isolated ATFL rupture

## Role of MRI?

1. To determine the sensitivity and specificity of MRI diagnosis of lateral ligamentous injuries as confirmed by EUA and arthroscopy findings
2. To define the prevalence of peronei tendons injury that coexist with lateral ligamentous injury
3. To compare the occurrence rates of other associated pathologies found on MRI to that of arthroscopy finding

# Ankle instability protocol (2004-)

- History-symptoms
- Clinical evaluation
- X-rays and MRI scan
- Evaluation under anesthesia
- Stress views in comparison with the normal ankle
- Arthroscopic confirmation & treatment
- Bostrom-Could reconstruction (CFL rupture)

## Inclusion criteria

- 1) no history of generalized ligamentous laxity
- 2) no history of generalized neuromuscular disorders
- 3) no prior surgery of the contra-lateral ankle
- 4) an uninjured contra-lateral ankle
- 5) no history of previous fractures of the involved ankle
- 6) no prior surgery other than an anatomic reconstruction, tenodesis, revision surgery of the involved ankle or simple ankle arthroscopy by other surgeons

## Patients (2004-2006)

- > 85 patients
- Average age 30 years (range 13-50 years)
- 50 ankles were injured during sport activities
- 35 ankles were damaged during military training
- Mean number of recurrent inversion injuries 2 (range 1-10)
- Mean duration of symptoms 38 months (range 6-168 months)

## Clinical evaluation

Tegner activity level scale

AOFAS ankle score

(preop, 3,6,12,24 months)

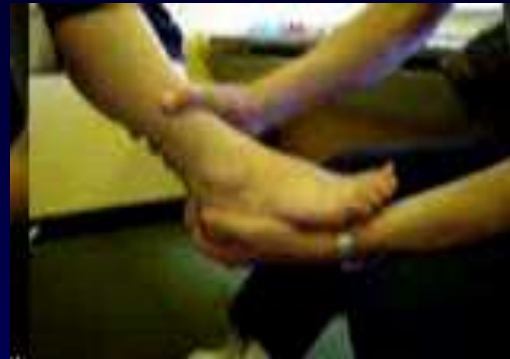# Statistical analysis

- ❖ Statistical analysis was performed using the SigmaStat software (SPSS Inc, Chicago, Ill, USA).
- ❖ Data were analysed with a 1-way analysis of variance (ANOVA) and the Student's *t* test.
- ❖ Non-parametric 1-way analysis (Kruskal-Wallis) was also used for arbitrary distributions.
- ❖ A *p* value less than 0.05 was considered statistically significant.

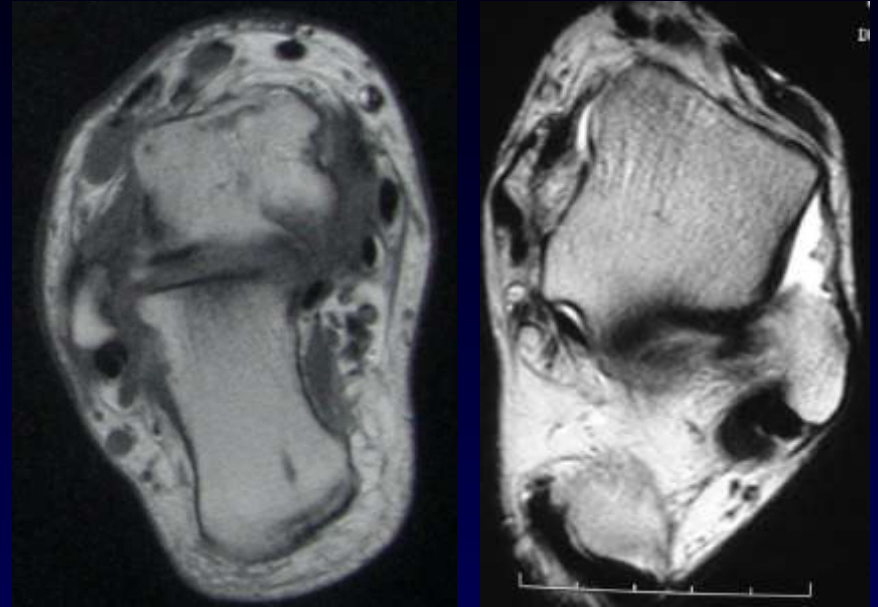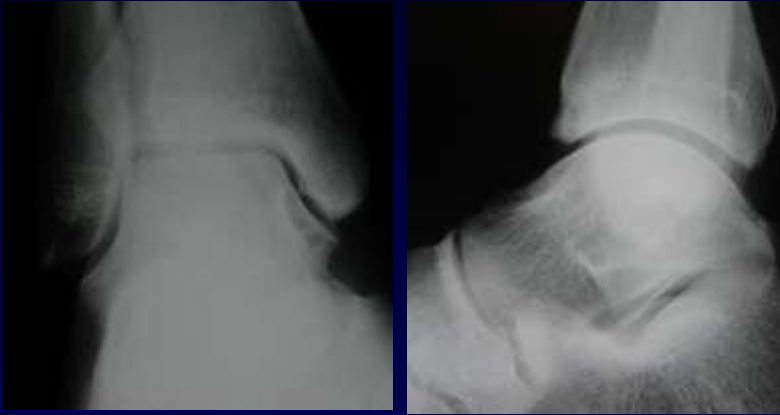


# History – clinical examination

- Postural & gait changes
- Ankle instability
- Subtalar joint motion
- Midfoot motion



## X-rays - MRI

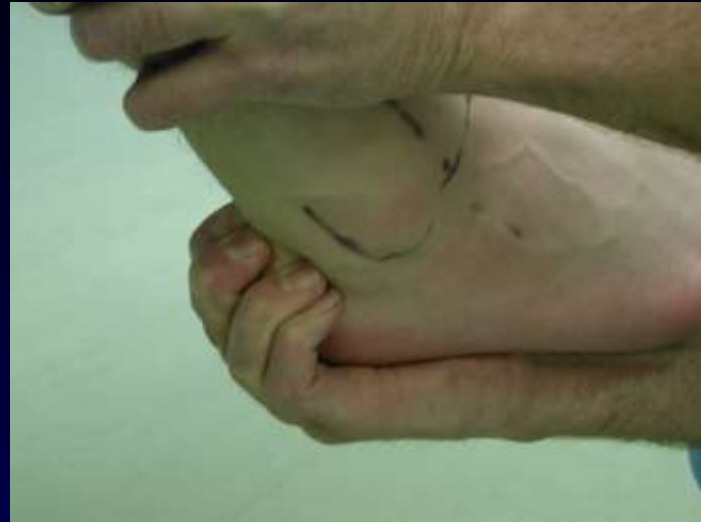

ATFL, CFL → 20° plantarflexion

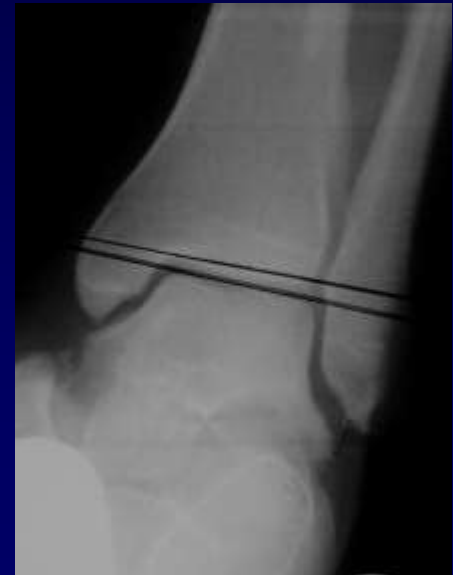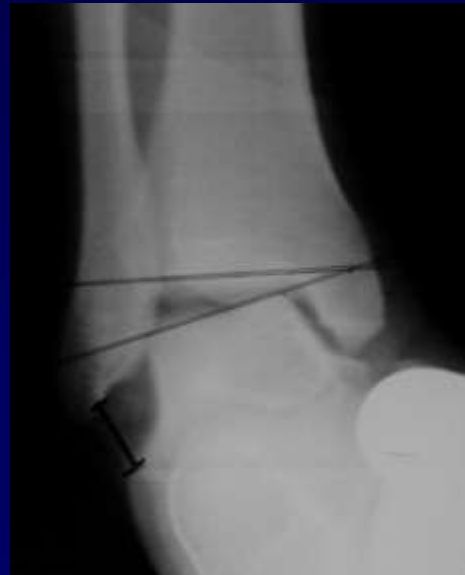
Peronei → 20° plantarflexion + 20° inversion

# EUA

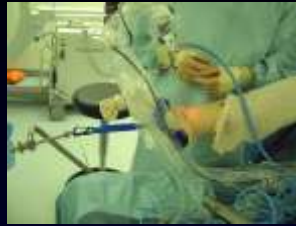- Anterior drawer test



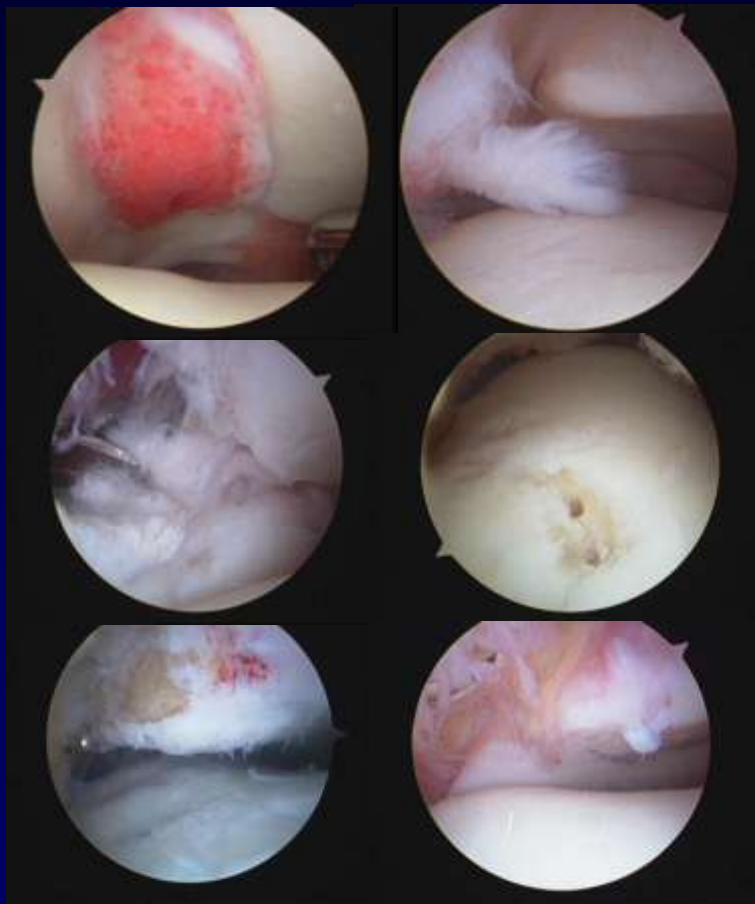- Lateral talar tilt test



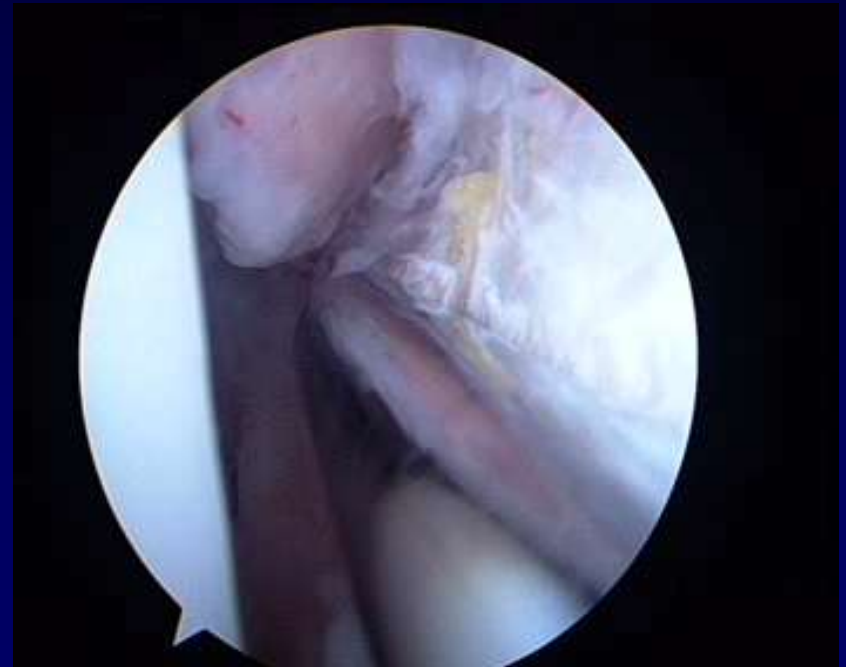# Arthroscopy



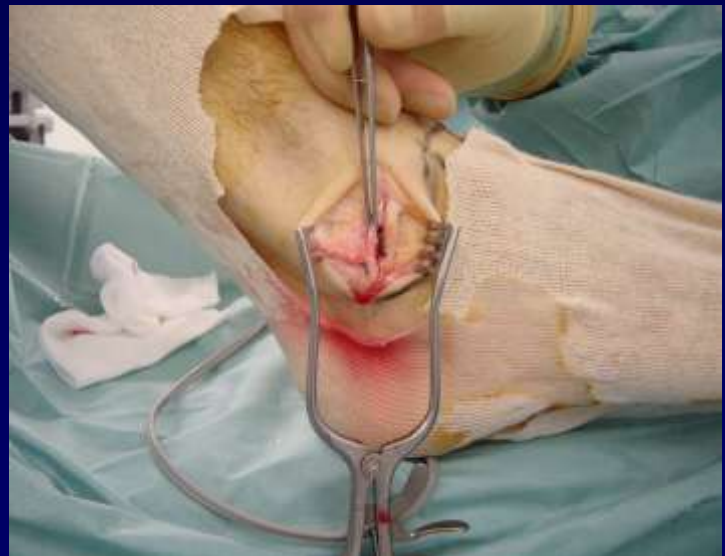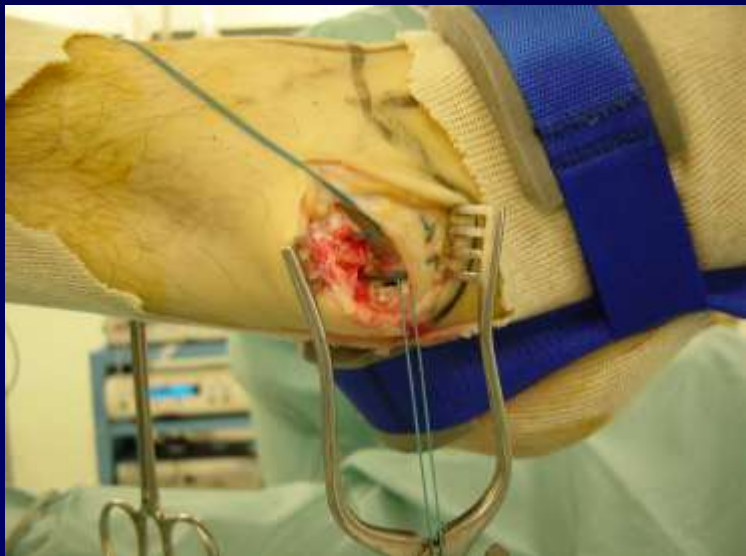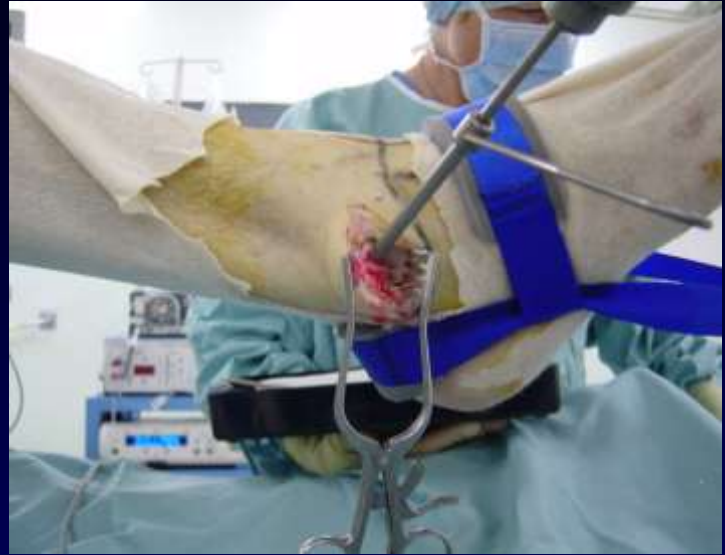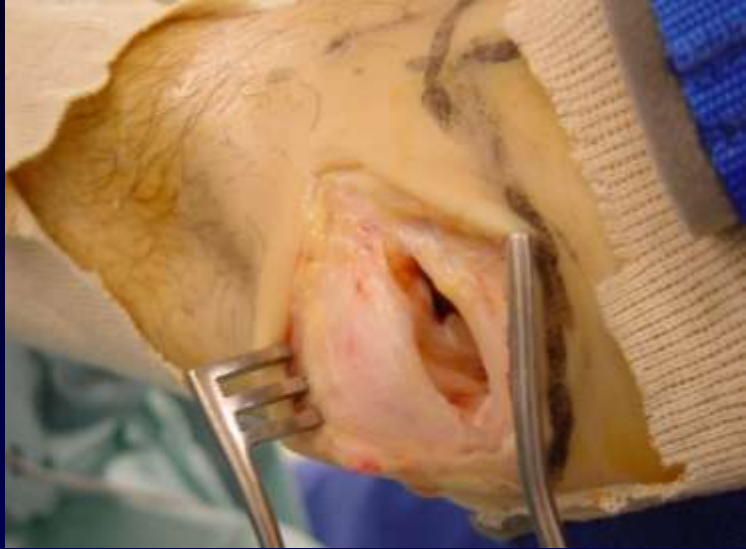- Functional instability



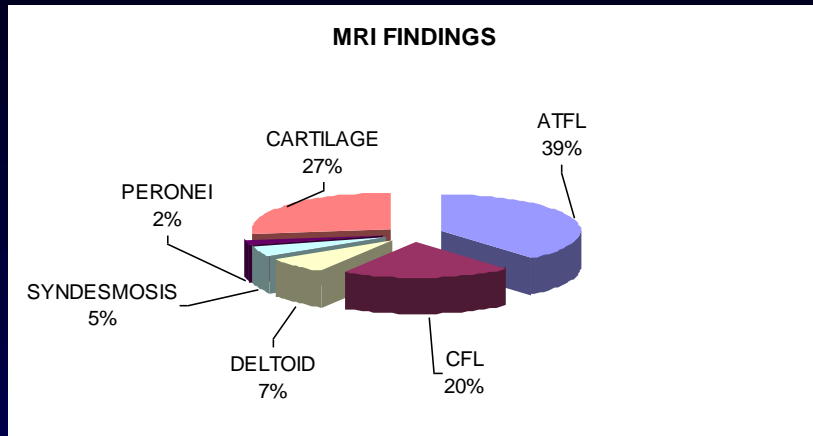
- Mechanical instability



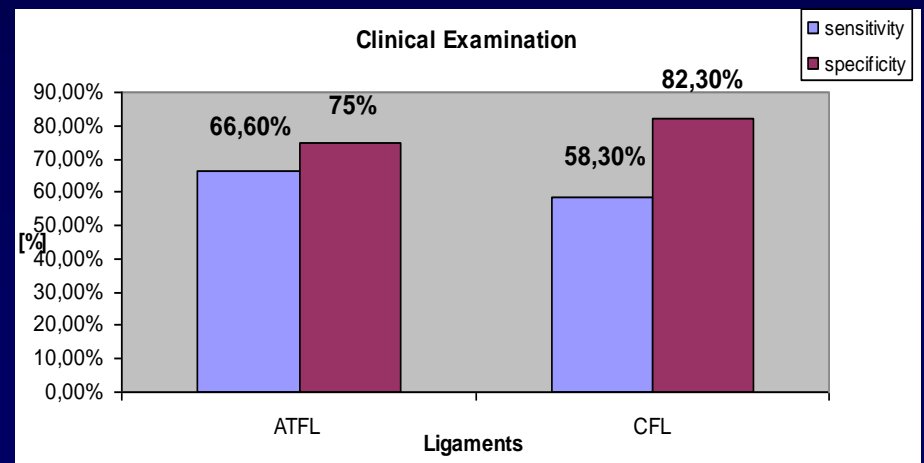
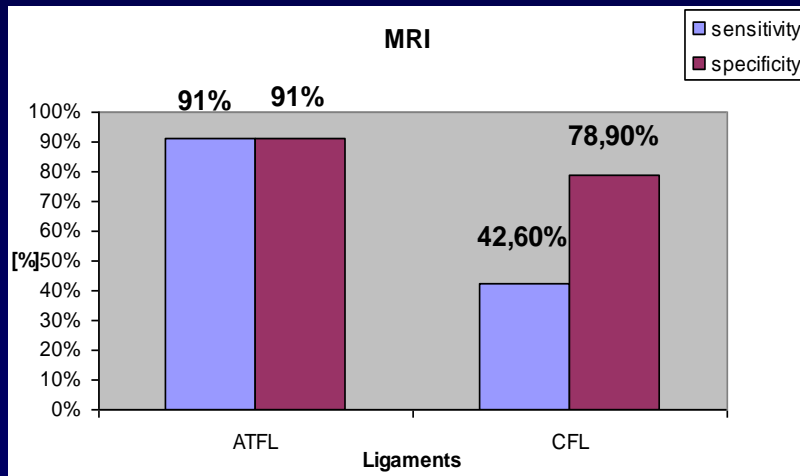
# Surgical technique



# MRI findings



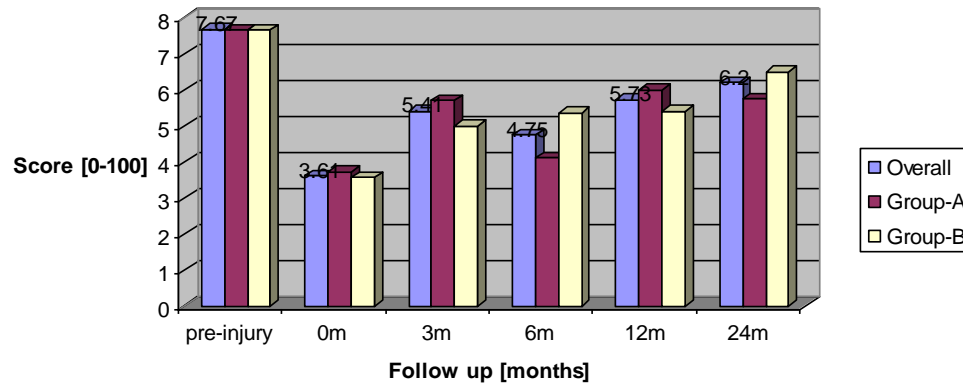
MRI has a high accuracy for ATFL injuries  
but low accuracy for CFL injuries





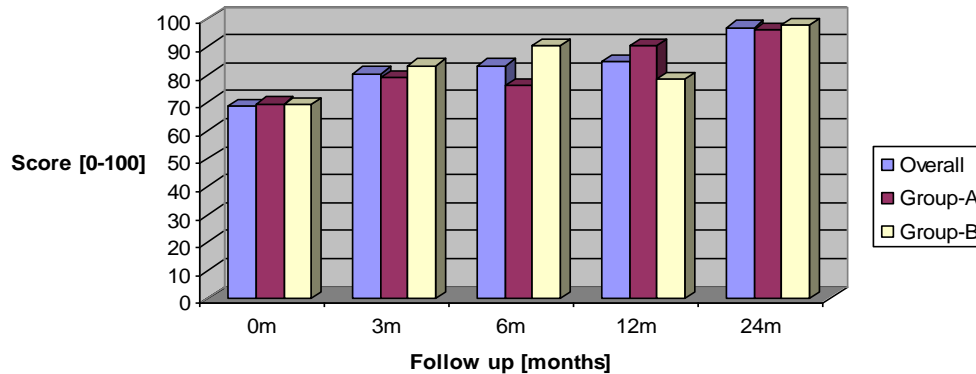
# Clinical results (mean follow up ~ 24 months)

Tegner Activity Level Score



Group A : Arthroscopy

AOFAS ankle-hind foot score



Group B : A/copy +  
Bostrom-Could

# Conclusions

- Our diagnostic and treatment algorithm for chronic ankle instability provides accurate evaluation of the deficient lateral ankle ligaments
- This study, demonstrated the excellent outcome of the anatomic lateral ankle ligaments repair in a high demand population
- The CFL ligament is the major restraint of lateral ankle instability and the pre-operative planning can be based on the integrity of this ligament.
- The associated intra-articular injuries may be a significant source of symptoms for this group of patients. Treatment of this associated pathology may provide excellent post-operative outcome.

# Limitations

- Could the final outcome be the same no matter the group of patients that treatment would be applied?
- Is arthroscopy only a sufficient treatment for both functional and mechanical ankle instability?
- A double blind study must be performed in which both treatment methods should be applied for both types of chronic ankle instability (ethical restrictions?)

## Expectations (research)

- The study will be completed (min. 3 years follow up) in 2008
- Preliminary results have already been presented in Hellenic Orthopaedic Association Meeting (Athens 2004), ESSKA 2006 Congress (Austria 2006) and Effort 2007 (Florence)
- Three papers are planned for submission to AJSM (Overall clinical study), Knee Surgery Sports Traumatology and Arthroscopy (role of CFL) and the Foot and Ankle Surgery (role of MRI)



Available online at [www.sciencedirect.com](http://www.sciencedirect.com)



Foot and Ankle Surgery 13 (2007) 171–176

---

FOOT AND  
ANKLE  
SURGERY

---

[www.elsevier.com/locate/fas](http://www.elsevier.com/locate/fas)

## Deficiencies of MRI in the diagnosis of chronic symptomatic lateral ankle ligament injuries

V. Kumar MRCS (Glasg), BTEC (sports)\*, I. Triantafyllopoulos MD,  
A. Panagopoulos MD, S. Fitzgerald FRCR, L. van Niekerk FRCS, FRCS (Tr & Orth)

*Centre for Sports Orthopaedics Surgery, Department of Orthopaedics, Friarage and Duchess of Kent Military Hospitals,  
North Yorkshire, United Kingdom*

Received 22 November 2006; accepted 17 April 2007

---

### Abstract

**Background:** Stress radiography and more recently magnetic resonance imaging have been used to study the integrity of lateral ankle ligaments in chronic symptomatic instability after injury.

**Aim:** Our aim was to see if magnetic resonance imaging was as good as examination under anaesthesia and stress radiography, for diagnosing injury to the lateral ankle ligaments.

**Methodology:** Fifty eight patients, 47 men and 11 women, who were athletes or military personnel, with symptomatic instability of their ankle were included in the study. This cohort of patients had MRI scans, stress radiography and arthroscopy of their ankle. Integrity of the calcaneo-fibular ligament (CFL) was recorded arthroscopically. The sensitivity, specificity, positive and negative predictive value of MRI and

## Results (N = 58 pt)

- 25 ATFL tears & 18 CFL tears.
- 7 isolated ATFL tears, no isolated CFL tears.
- 18 had both ATFL and CFL tears.
- 18 patients underwent reconstruction of CFL (Bröstrum)

<b>Lesions picked up</b>	<b>MRI</b>	<b>Arthroscopy</b>
<b>Deltoid ligament lesion</b>	<b>3</b>	<b>3</b>
<b>Syndesmotic lesion</b>	<b>2</b>	<b>2</b>
<b>Peroneal tendon abnormalities</b>	<b>2</b>	<b>2</b>
<b>Cartilage lesions</b>	<b>19</b>	<b>24</b>
<b>Loose bodies</b>	<b>6</b>	<b>10</b>
<b>Synovitis / hypertrophy</b>	<b>18</b>	<b>22</b>
<b>Osteophytes</b>	<b>14</b>	<b>17</b>



# Results

**Table 1: Comparison of MRI and EUA ( arthroscopy as gold standard)**

		MRI	EUA ( + stress radiographs)
ATFL <sup>†</sup>	Sensitivity	87% (CI 73-100)*	83% ( CI 68-99)
	Specificity	60% (CI 43-77)	91% ( CI 81-100)
CFL <sup>‡</sup>	Sensitivity	47 % (CI 23-71)	94% (CI 83-100)
	Specificity	83% (CI 71-95)	98% (CI 93-100)

*\* indicates 95% Confidence Intervals*

<sup>†</sup> *Anterior Talo-Fibular Ligament*

<sup>‡</sup> *Calcaneo-fibular ligament*

**Table 2 : Comparison of Accuracy of MRI and EUA**

	MRI	EUA ( stress radiographs)
ATFL <sup>†</sup>	71% (CI 59-83)*	88% (CI 79-96)
CFL <sup>‡</sup>	72% (CI 61-84)	97% (CI 92-100)

*\* indicates 95% Confidence Intervals*

<sup>†</sup> *Anterior Talo-Fibular Ligament*

<sup>‡</sup> *Calcaneo-fibular ligament*

# Results

**Table 3: Comparison of predictive values of MRI and EUA**

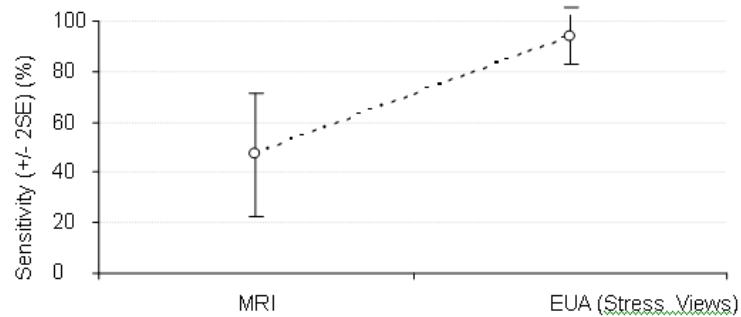
		MRI	EUA (Stress radiographs)
ATFL †	PPV	59% (CI 42-76)*	87% (CI 73-100)
	NPV	88% (CI 74-100)	89% (CI 78-99)
CFL ‡	PPV	53% (CI 28-79)	94% (CI 83-100)
	NPV	79% (CI 67-91)	98% (93-100)

\* indicates 95% Confidence Intervals

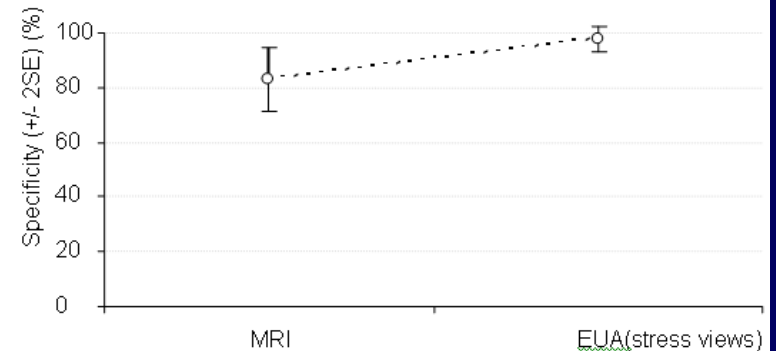
† Anterior Talo-Fibular Ligament

‡ Calcaneo-fibular ligament

PPV denotes Positive Predictive Value and NPV denotes Negative Predictive Value



**Figure 1: Sensitivity of MRI and EUA for the Calcaneo-fibular ligament.**



**Figure 2: Specificity of MRI and EUA for the Calcaneo-fibular ligament.**

# Limitations

- Absence of control group without symptoms of instability  
(ethical issues regarding MRI and stress X rays in asymptomatic)
- No standardised measurements to measure mechanical ankle instability  
( Figures quoted in literature varied, hence comparison with normal side used)
- Absence of standardised stress apparatus
- MRI ( static investigation) versus Stress radiographs ( dynamic investigation)  
(reflects current practice)

# Conclusion

- MRI has no distinct advantage over EUA & stress radiography in diagnosing chronic (grade 3) ligament deficiency
- MRI useful to plan surgery by picking up associated lesions.
- Dynamic measurements such as dynamic MRI and MRI arthrogram may be more accurate in assessing integrity of ankle ligaments.
- EUA & Stress radiographs have excellent sensitivity, accuracy and predictive value in assessing integrity of the CFL.

THANK YOU

